Digitized by the Internet Archive
in 2013

http://archive.org/details/thyroidglandofat00hoar

BOSTON UNIVERSITY

GRADUATE SCHOOL

Dissertation

THE THYROID GLAND OF THE ATLANTIC SALMON

by

William Stewart Hoar

(B. A., University of New Brunswick, 1934;
M. A., University of Western Ontario, 1936)

submitted in partial fulfilment of the

requirements for the degree of

Doctor of Philosophy

1939

4556

PhD
1939
ho
copy 1

APPROVED

by

First Reader.....Alice S. Woodman, M. D.
Associate Professor of Histology
and Embryology

Second Reader Leland L. Wyman
Associate Professor of Physiology

TABLE OF CONTENTS

Page

Introduction 1

Materials and Methods. 2

Development of the Thyroid 7

Literature 7

Embryological Findings in Salmo salar. 14
Previous to Appearance of Thyroid. 15
Appearance of Thyroid. 16
Separation of the Anlage 18
"Migration" of the Anlage. 19
Break-up of the Anlage 21
44 day Sandwich embryos. 22
51 day Sandwich embryos. 24
65 day Sandwich alevin 27
86 day Sandwich alevin 29
32 week Saint John salmon fry. 29

Discussion of Development. 32

Gross and Microscopic Anatomy. 39

Literature 39

Distribution of Thyroid Tissue 50

Histology. 53

Vascularity. 56

Innervation. 60

Histophysiology. 60

Seasonal Changes 63

Metamorphosis. 65

Sexual Maturation. 70

Discussion 72

Abstract 75

TABLE OF CONTENTS (Cont'd)

Page

Acknowledgments 81

Bibliography. 82

Illustrations 94

Figure 1a Graphic reconstruction of the thyroid anlage of the 12 week St. John embryo . 94

1b Graphic reconstruction of the same structures in the 14 week embryo. . . . 94

Figure 2 Wax model of the pharyngeal floor of the 12 week embryo 95

Figure 3 Photomicrograph of the primary thyroid anlage. 96

Figure 4 Photomicrograph to show the differentiation of the attached anlage 96

Figure 5 Photomicrograph of the detached and solid anlage. 97

Figure 6 Photomicrograph of an anomalous mass of thyroid tissue 97

Figure 7a Graphic reconstruction of the thyroid of the 44 day Sandwich embryo 98

7b The thyroid of the 51 day Sandwich embryo. 98

7c The thyroid of the 65 day Sandwich alevin. 98

7d The thyroid of the 86 day Sandwich fry. 98

Figure 8 Photomicrograph showing the morphogenesis of the thyroid follicle 99

Figure 9 Photomicrograph showing developing follicles and lymphatics.... 99

Figure 10 Graphic reconstruction of the thyroid of the 32 week Saint John fry 100

Figure 11 Photomicrographs of the thyroid of the 32 week Saint John fry 101

Figure 12 Graphic reconstruction of the thyroid of an 11.1 cm. parr 102

TABLE OF CONTENTS (Cont'd)

Page

Figure 13 Graphic reconstruction of the thyroid of a 15.4 cm. smolt. 103

Figure 14 Photomicrographs of the thyroid of the 11.1 cm. parr 104

Figure 15 Photomicrographs of the thyroid of the 15.4 cm. smolt 105

Figure 16 Photomicrographs of the thyroid of an 80 cm. adult salmon 106

Figure 17 Graphic reconstruction of the thyroid lymph sinus of a 15.4 cm. smolt. . . . 107

Figure 18 Photomicrograph of the thyroid of a 14.2 cm. smolt 108

Figure 19 Photomicrograph of thyroid follicles of a 10.2 cm. parr 108

Figure 20 Photomicrograph of thyroid follicles of a 13.2 cm. smolt. 109

Figure 21 Photomicrograph of thyroid follicles of a 90 cm. adult salmon 109

Figure 22a Photomicrograph of the testis of an 11.1 cm. parr 110

22b Photomicrograph of the testis of a 10.1 cm. parr 110

Figure 23a Photomicrograph of the testis of a 12.5 cm. parr 111

23b Photomicrograph of the ovary of a 13.2 cm. parr 111

Autobiography 112

THE THYROID GLAND OF THE ATLANTIC SALMON

INTRODUCTION

The presence of the thyroid gland in teleosts was first noted less than one hundred years ago by John Simon (1844). This investigator believed the organ to be absent in salmon and trout. This belief was soon found to be erroneous, and its presence in the vertebrates has long been recognized as universal. Although the literature on thyroid anatomy published during the latter half of the nineteenth century is considerable, the teleosts as a group have received little attention. Gudernatsch (1911) made an outstanding contribution when he compared the thyroids of 29 species of teleosts, and gave a comprehensive review of previous findings. In regard to the embryology of the organ, Maurer (1886) seems to have made the sole contribution of any account. Although Gudernatsch dealt in particular with the genus Salmo and Maurer studied the trout, Salvelinus fontinalis, the former does not mention the Atlantic salmon (Salmo salar, Linn.), nor do my embryological findings accord with those of the latter for this closely related species. Physiological investigations on the teleostean thyroid have been very few. As far as I have been able to ascertain this organ has never been investigated in relation to the life history of Salmo salar.

In the first place, then, this paper will consider in some detail the developmental, gross and microscopic anatomy of the salmon thyroid gland. This will be followed by a histophysiological study of the organ in relation to the activities and life history of the fish.

MATERIALS AND METHODS

The embryological studies are based on two series of salmon embryos, both obtained from the Saint John Fish Hatchery, Saint John, N. B. The first series was preserved in Bouin fluid at the hatchery in 1934-1935, while the second was shipped after fertilization to the State Fish Hatchery, Sandwich, Mass., and hatched there in 1936-1937. Only the early stages of the former series were available. The latter series is quite complete, with weekly samples from November 25th to April 28th. The material, with the age, length, and simultaneous temperature of the hatchery water is listed below.

It will be seen from this table that the incubation period of the Sandwich fish is much shorter. Since the hatchery water at Sandwich, Mass., is approximately 10° C. higher than that at Saint John, N. B., this is to be expected. The effect of temperature on metabolic activities is well known. Several workers have studied the relation of temperature to the incubation periods of trout and salmon (Embody, 1934; Merriman, 1935). Belding et al (1932),

studying the Atlantic salmon, found that water temperatures below 5° C. were not a prominent factor in determining the incubation periods. However, above that point they were of great importance. Thus, at 2° C. the incubation period was found to be 191 days, at 4° C., 170 days; at 6.5° C., 88 days, and at 10° C., 58 days. The present data show a similar shortening. The fish hatched in 59 days at Sandwich, Mass., with the water at approximately 10° C. as compared to 175 days at Saint John, N. B., where the water approximates 0.4° C. during the incubation period.

It is evident that not only is the incubation period shortened, but that also the rate of growth is considerably augmented by the higher temperatures. The tissues themselves seem somewhat less differentiated and the boundaries less well marked in the more rapidly developing individuals. However, it was only in the last specimens obtained (March and April) at Sandwich that anything of a definitely pathological nature was evident. These later ones have not been used in the studies but Saint John fish substituted in their place. Also, Saint John hatched fish were used for the early embryological studies since these stages were passed through too rapidly at Sandwich to be followed with any degree of accuracy.

Age-length relationship of the developing Salmon

SAINT JOHN FISH			SANDWICH FISH*		
Age of Specimen	Length of Specimen	Temperature of hatchery water	Age of Specimen		Length of Specimen
Weeks	mm.	°C.	Days	Weeks Approx.	mm.
0(Nov. 8/34)	0.0	7.3 - 7.0	0(Nov. 9/36)		0.0
4	4.2	0.9 - 0.9			
5	4.9	0.4 - 0.4			
6	5.5	Temperature			
7	6.3	constant	30		6.0
8	7.3	until the			
9	7.8	24th week			
10	8.0		37		8.0 - 9.0
11	8.5				
12	8.8				
13	8.8				
14	9.0				
15	10.0				
16	10.5				
17	11.0		44	6	11.1
18	11.3				
19	12.3				
20	12.5				
21	13.0				
22	13.5		51	7	13.5
23	14.0				
24	15.5	0.9 - 0.4	65	(hatching)	15.8
25(hatching)	19.0	7.6 - 6.5	72	9	16.1
26	22.0	8.8 - 8.1	79	10	19.6
27	23.8	10.1 - 9.9	86	11	21.1
28	25.8	11.1 -11.1	93	12	22.6
29	27.2	14.2 -13.8	100	13	23.8
30	28.8	19.1 -18.8	107	14	25.2
31	27.6	17.6 -17.6	114	15	25.8
32	28.4	15.5 -15.5	121	16	26.9
33	31.3	18.8 -18.8	128	17	27.0
			135	18	27.3
				24	29.7

*Note - The temperature of the hatchery water at Sandwich, Mass., is kept constant at 10° C.

A number of different fixatives were tried on the embryonic material obtained from Sandwich, Mass. The Henneguy method for fish eggs gave very good results. Generally, however, Bouin fixation seemed to be the best for salmon tissues. Formol in saline was quite satisfactory, but the Zenker and Helly fixations did not work as well. Some of the material was stained in bulk with alum cochineal - counter-stained with orange G., and some with hematoxylin and eosin. The latter combination is preferable for microscopic study, projection or photographing. Studies were made from serial sections cut transversely, sagittally, or frontally, and usually at 10 μ.

The larger salmon - fry, parr, smolt and adults - were collected from the Margaree River system in Nova Scotia, during the summers of 1936 and 1937. This collection was supplemented by a very few mature specimens from the Bay of Fundy in 1938. Bouin or formol in saline were the usual fixatives. A few specimens were preserved in Zenker and Helly fixing fluids to facilitate certain staining techniques. The bulk of the material was stained routinely with hematoxylin and eosin. Verhoff's elastic and Mallory's connective tissue stains were used to identify the connective tissue fibers. Nerves and nerve endings were studied by a modified Bielchowsky technique. It would have been desirable to have attempted staining for certain of the cytological constituents such as mitochondria

and Golgi apparatus. However, collecting the material in the field, far from the laboratory, did not permit this and I was forced to rely on such evidence as could be gleaned from the routine methods of preparation.

Because of the diffuse nature of the teleostan thyroid the glands had to be studied from serial sections and reconstructions. Only in very large salmon - 80 to 100 cm. - can one see the thyroid with any degree of satisfaction, and even then the details of its boundaries must be traced microscopically. Graphic reconstructions were found to be most satisfactory for mapping the organ. The following procedure was followed in preparing the illustrations of the thyroid region. The sections were projected at the desired magnification and drawn serially; each drawing being subsequently checked under the microscope. The mid line of the drawings - based on the position of the basibranchial cartilages and the ventral aorta - was then established and the distances of the structures to be plotted measured from this line. The measurements thus obtained were then plotted to scale with an arbitrary line as a basis. Photomicrographs taken at the levels indicated on the reconstructions aided in obtaining the three dimensional picture.

The wax reconstruction of the early thyroid anlage, illustrated in figure 2, was prepared according to the well known method of Born (Minot 1903).

All photomicrographs were taken with a Bausch and Lomb instrument. The liquid filter recommended by Mallory (1938) was used throughout. The staining combinations and magnifications have been indicated on the individual photographs.

DEVELOPMENT OF THE THYROID

It is generally stated that the thyroid gland arises, as a proliferation of cells, from the mid-ventral floor of the pharynx at the level of the first pharyngeal pouch. It should be mentioned, however, that there is no absolute agreement on this question. Lateral contributions from the so-called ultimobranchial bodies are still stressed by some. Thus,Weller (1931) studying human embryos; Badertscher (1918) pig embryos; and Rogers (1927) working on the white rat, are but a few of those who trace the origin of small portions of the gland from these bodies. More recently Kingsbury (1935), on the basis of an exhaustive study of human material, has refuted the work of these writers. He findsthat after fusion with the medial thyroid the ultimobranchial complex undergoes reticulation and degeneration.

On the other hand, Norris (1937) in an equally detailed and comprehensive study of human material cound find no evidence of degenerative changes in the "lateral thyroids". He concludes that these two bodies together form about one-third of the follicular tissue of the thyroid of the human foetus, and that they do contribute in an essential manner

to the parenchyma of the definitive gland. Opinion is thus divided at the present time, although the majority of text-books stress the single focus of origin. Whatever may be the ultimate conclusion of the matter in relation to the mammalian thyroid, it seems to be a matter of general agreement that these bodies do not enter into a consideration of the problem in the lower vertebrates. They are, nevertheless, present in all classes except the cyclostomes (Watzka, 1933), remaining as distinct and separate bodies of unknown function at the cranial end of the pericardium. Watzka (1933) discusses the position, fate, and structure of this complex in the lower vertebrates.

The literature indicates that the details of thyroid development among the fishes vary considerably. Among the cyclostomes, Bdellostoma stouti shows an elongated trough-like anlage, arising as a downpocketing from the floor of the pharynx throughout the entire gill area (Stockard, 1906). In the larval Petromyzon (Ammocoetes branchialis) the connection with the pharynx is retained. The loss of this embryonic connection, together with certain histological changes at the time of metamorphosis, have formed the basis for the phylogenetic origin of this organ from the endostyle of the lower chordates (Marine, 1913).

Norris (1918) has given a detailed account of the embryology of the thyroid gland in the elasmobranch, Squalus acanthias. In embryos of 4 mm. a solid epithelial bud

arises from the floor of the pharynx. This cellular proliferation is located just ventral to the point at which the oesophagus leads from the pharynx and in the region inferior and caudal to the ventral extremeties of the first two pairs of gill pouches. No groove or pouch is formed. The connection with the pharynx is lost at the 19 mm. stage, leaving no thyreoglossal duct.

Of the ganoids, the embryology of only one form, Amia calva, has been investigated. Hill (1935) found the thyroid in this form to originate as a solid mass of yolk-laden entoderm from the mid portion of the floor of the pharynx, at the level of the first and second visceral pouches. The anlage, appearing when the embryo is 6 to 6.5 mm. long, is usually single but sometimes shows small accessory masses. This anlage is in contact with the pericardium ventrally and attached to the truncus arteriosus at its bifurcation. It is apparently pulled loose from the pharyngeal floor by this attachment. It leaves no thyreoglossal duct.

The only detailed account of teleostean thyroid embryology was published by Maurer in 1886. In the trout (Salvelinus fontinalis) he found that the gland appears about 26 to 28 days after fertilization, when the embryo is 6 mm. long, as a median downpocketing from the ventral floor of the pharynx between the first and second gill pouches. This downpocketing appears in the curve of the S-shaped tubular heart. At 35 days this vesicular anlage has sepa-

rated completely from the pharynx. As a solid spherical structure it then begins to grow by budding. His illustrations show a very definite and vesicular evagination in the 30 day trout. Greil (1906) in his study of the foregut derivatives of Ceratodus states that the thyroid appears as a solid body from the ventromedian border of the digestive tube between the ventral ends of the first gill pockets. A small cavity appears in this solid cell complex before the separation from the floor of the pharynx is complete. Gudernatsch (1911) in his survey of the teleostean thyroid agrees with Maurer's view on the early embryology in this group, and tends to repudiate Greil.

Thus we find that in four of the different groups of Pisces, Cyclostomata, Elasmobranchii, Ganoidei and Teleostei, three different modes of origin of the thyroid have been described. In the elasmobranch and ganoid the anlagen were found to be solid. In the cyclostomes and teleosts evaginations are described, but these differ in that in the former it is trough-like in form, while in the latter it is vesicular. It is interesting to note that among vertebrates above the Pisces in the phylogenetic scale similarly differing types of primordia have been found. Thus, among the amphibia the anlage is solid (Platt, 1896; Sanders, 1931, etc.) while in reptiles, birds, and mammals, it is usually described as being vesicular in nature (Gudernatsch, 1911).

The most widely accepted work on the morphogenesis and

histogenesis of the thyroid gland is that of E. H. Norris. He has studied the process in detail as found in man (1915 and 1918a) and in the dogifsh, Squalus acanthias (1918b). The findings in these two widely separated species are similar. According to this writer the course of events is the same in the pig, sheep, dog, and pigeon (Norris, 1918a). Whether the anlage is a solid proliferation of cells, as found in the dogfish, or a shallow diverticulum,as seen in the mammals, it early assumes the form of a solid mass of epithelial cells ventral to the pharynx. Within this solid body of tissue a number of completely closed cavities then appear. These intraglandular cavities increase in size, form intercommunications one with another, and eventually open to the outside of the formerly solid mass. The mesenchyme invades the spaces thus formed. Hence the gland is transformed from a solid body, first into a hollow one and eventually into a system of epithelial bars and plates two cells in thickness.

The transient intraglandular cavities have nothing to do with the formation of the follicles themselves. According to Norris (1916) these arise in man as independent structures from the epithelial plates by rearrangement of the cells, proliferation and increase in the size of the cells, and the formation of lumina by a simple withdrawal of the central ends of prefollicular spherules. The findings for the dogfish are similar (Norris, 1918b). In both

cases the colloid appears some time after the formation of primary follicles. In the dogfish secondary follicles are formed through budding (Norris, 1918a). In man solid buds formed on the follicular wall may separate from the follicle while still solid or form a lumen before separation, or they may arise directly as hollow buddings (Norris, 1916). Division of the parent follicles through constriction is also described (Norris, 1916). In no case could this writer find evidence for the formation of thyroid follicles directly from the primitive saccular thyroid anlage.

Bradway (1929) has described a similar morphogenesis for the chick thyroid. In this form however the primary acinar cavities are seen to be formed by secretion and coalescence of two droplets of chromophobe colloid. Uhlenhuth (1927) has described a similar genesis of the primary follicles in the salamander thyroid.

This morphogenesis, however, as set forth by Norris does not seem to be the course of events in all vertebrates. In the cat, Ramsay (1938) describes the origin of primary follicles by hollow budding and constriction directly from the open thyroid diverticulum. He believes this to be the primitive method of follicle formation, and the process as seen in certain other mammals and as described by Norris, to be a slurring over of the fundamental growth relationships with the addition of new paths. Ramsay believes that there is great variation among the different animals and

describes three processes: in the calf, growth by way of plates and bands one cell thick; in man, plates and bands irregularly branched and two cells thick; and in the cat, growth of buds and sprouts from the plates and bands or directly from the diverticulum.

It should be pointed out that none of the recent work subscribes to the earlier conception of follicle formation through the intermediary of hollow tubes. Müller (1871) one of the first investigators of thyroid development believed that all glands went through three stages: viz., severing of the anlage from the pharynx, formation of a network of tubes of glandular epithelium, and the formation of follicles from these tubes. The network of tubes is now seen to be a network of bars and plates. These are not universally present (Ramsay, 1938).

Aside from Norris' work on the dogfish, already referred to, studies of thyroid histogenesis among the Pisces have not been common. Maurer (1886) describes solid epithelial proliferations from the wall of the primary pharyngeal outpocketing in the trout. These acquire lumina and are pinched off from the anlage as separate follicles. A lightly refractive material may collect in these even before separation from the mother vesicle. Gudernatsch (1911) subscribes to this view of the budding of the primary follicles from the original evagination. Hill (1935), studying Amia calva, describes a simple process of follicle

formation by the accumulation of colloidal material between the cells of the primary solid diverticulum. Secondary follicles arise through division of the primary acinus through simple constriction. Hill finds no evidence of the solid buds described by Maurer. Florentin (1932) from a study of seven species of teleosts, concludes that primary follicles are formed by a simple budding of the anlage and that secondary follicles likewise form from a budding of the primary acini. He believes that the budding and position of the new follicles are determined by the numerous capillaries which surround the anlage.

The concensus would seem to be then that the teleosts show a much simpler genesis of thyroid follicles than do the elasmobranchs, or do the higher vertebrates.

Embryological Findings in Salmo salar.

The development of the thyroid of the Atlantic salmon can be divided into nine stages, which seem to differ essentially, but not so greatly that the process cannot be followed readily from stage to stage. The thyroid regions in these stages of development will first be described in detail. Following will be a general discussion of the findings. Since the early organogenesis can be followed more readily in embryos hatching at the slower rate, Saint John fish have been used for early stages up to the time when follicles are beginning to appear and when the fish is about 11 mm. long.

Stage I - Previous to Appearance of Thyroid - 8.0 mm. - 10 weeks

No evidence of thyroid can be found in embryos preserved at Saint John 10 weeks after fertilization. It seems well, however, to summarize briefly the state of development of certain of the landmarks in the thyroid region of these fish.

The pharyngeal area is poorly formed. The pharynx is still quite solid, while the arches and future gill slits are only marked out laterally and cranially. Four arches are recognizable as masses of compact but undifferentiated lateral mesoderm with the epithelial pouches and grooves still solid between. The hyoid and third arch are best differentiated with the cleft between partially broken through. The mandibular and fourth arch are well marked but the fifth is only indicated. The maxillary process of the future upper jaw is merely suggested at its lateral boundary.

In the dorso-cranial part of the embryo the three primary brain vesicles may be made out. Prominent eyes contain clearly marked lenses, which however are not yet entirely detached from the superficial ectoderm.

Of particular interest because of their subsequent relation to the thyroid are the heart, and vessels developing in connection with it. The heart is recognized as a simple undifferentiated but bent tube. The greater part of the organ lies to the right of the mid-ventral line. The simple tube has been bent into the form of a 'U', the

blind end of which is forced far cranially by the mass of ventral yolk. Thus the heart may be described as an S-shaped organ lying to the right side of the mid line and mostly craniad to its point of attachment. Vitellinevessels can be traced to the caudal end of the organ, but the arterial connections do not seem to be completed. Twigs of the future hyoid arteries can be traced for a short distance cranially from the truncus arteriosus, but for the most part only isolated clefts of the future vessels are found in the hyoid arch. No vascular channels can be made out in the arches behind the hyoid.

Stage II - Appearance of the Thyroid - 8.5 mm. - 11 weeks.

Thyroid tissue may be readily identified in embryos of 11 weeks, indicating that the organ arises sometime between the tenth and eleventh week, and when the embryo is about 8.5 mm. long.

Neighboring structures in the head region show little development beyond that described for the ten week fish. The mesoderm of the future branchial arches has increased somewhat in amount, and one additional arch (number V) has been blocked out, but there is no indication of cartilage formation or of the development of the copulae ventrally. The lens of the eye has become detached. The pharynx is solid. The hyoid vessels show considerable further development in the 11 week embryo, the truncus arteriosus having become continuous with these two large arteries which can

be traced cranially into the hyoid arch to the region of the hyomandibular cleft (fig. 1a). No blood vessels are yet apparent in the arches posterior to the hyoid.

The thyroid itself makes its appearance as a solid knob-like proliferation of the entoderm of the floor of the foregut. This proliferation occurs in the mid-line, at the posterior border of the hyomandibular junction and grows into the crotch of the two vessels just described (figs. 1a, 2, and 3). The boundaries of this mass are very ill-defined. It appears as a mound of nuclei, connected to the pharyngeal epithelium and pressed into the bend of the S-shaped heart. It extends through six 10 μ. sagittal sections and is about 75 μ. long. This mass is forced into a somewhat triangular shape by the truncus arteriosus caudally, the oral epithelium dorsally and the blind end of the heart ventrally (fig. 3).

The cells of the anlage have the cytological characteristics of rapidly dividing embryonic tissues. Cell boundaries are apparently absent. The nuclei are oval to round in shape, with clearly marked nuclear membranes and one or two fairly large, often angular masses of chromatin. This type of nucleus seems fairly characteristic of the entodermal organs at this time. The cytoplasm of the cells of the anlage is scanty, the nuclei forming rather a compact mass with no evidence of the definite arrangement to be described in the next stage. Mitotic figures are common.

Stage III - Separation of the Anlage - 8.8 mm. - 13 weeks.

Differentiation in the head region has progressed considerably. Dorsally the different parts of the brain are well mapped out and the buccal portion of the pituitary is quite evident (fig. 4). Ventrally, four masses of mesoderm behind the future hyoid arch indicate that all the branchial arches have made their appearance. The epithelial pouches and grooves of the future gill slits are evident, but a rupturing has occurred only in the case of the first true slit. Although the pharynx is essentially a solid structure, numerous clefts are appearing in the mass of cells between the future roof and floor epithelium. These latter indicate clearly the boundaries of the future pharynx (fig. 4). The isolated clefts are more numerous laterally indicating that the separation of the epithelium occurs there first. Blood vessels forming in the mesoderm of arches III and IV may be recognized, but these are not as yet in communication with the heart. The only prominent vessels arising from the truncus arteriosus are the two large hyoid arteries already described (fig. 1a).

The thyroid gland is becoming detached from the oral epithelium at this stage. Of the two specimens examined, one showed an attached and one a detached anlage (figs. 4 and 5). The attached anlage, although of about the same size as the primary proliferation seen in stage II, is very much more clearly differentiated and delimited from the surround-

ing tissues (cf. figs 3 and 4). It appears as an elongated bud or knob occupying essentially the same position as the anlage of the 11 week fish. The caudal tip of the bud has come to lie ventral to the aortic bifurcation. The cells of the anlage have become more definitely arranged. A single layer of entodermal nuclei of the type already described, surrounds the structure, while a relatively clear area of cytoplasm may be made out inthe center (fig. 4). The cell boundaries, however, are quite indistinct.

The general relations are essentially the same in the specimen with the detached anlage. However, the thyroid has become separated from the solid pharynx; and the nuclei of the oral epithelium form an uninterrupted layer over the anlage. Nevertheless, the organ is in very intimate contact with this epithelium. Its positional relations with the heart are the same as in the other specimen.

No cavities, follicular or non-follicular, are discernible in the anlage. Mitotic figures seem to be less numerous than in the primary proliferation.

Stage IV - "Migration" of the Anlage - 9.0 mm. - 14 weeks.

Although the pharynx is not yet open an almost complete cleft can be traced caudal to the region of pouch IV. The second true gill cleft shows signs of rupturing. The maxillary process of the upper jaw is clearly marked laterally as a mass of concentrated mesoderm. The arteries of arches III and IV are connected to the truncus arteriosus, while iso-

lated clefts of the vessel developing in arch V are evident.

In the mid line and ventral to the floor of the pharynx in the region of the mandibular, hyoid and first true gill arch there has been a considerable growth of mesoderm (figs. 4 and 5). This is due to the development of the copulae, in particular the basihyoid and the mandible. Moreover the hyomandibular complex has grown cranially so that the now detached thyroid anlage lies relatively caudal to its former position and almost at the caudal border of the basihyoid cartilage. The thyroid anlage is now bounded caudally by the truncus arteriosus, cranially and dorsally by the middle and posterior ventral portions of the basihyoid, and ventrally by the body wall (fig. 5). The lateral and most caudal portions of the anlage lie ventral to the truncus arteriosus at its bifurcation. The cranial and medial portions lie somewhat more dorsally and in front of the bifurcation (fig. 1b).

The boundaries of the anlage are clearly outlined. The organ is oval in shape and about 100 μ. long by 80 μ. wide (fig. 5). The cytological characters are in general the same as those described for the last stage. However, in a few places the rearrangement of the nuclei in an acinar manner is suggested. Also, small non-follicular cavities may be seen in the clearer central portion of the anlage. Mitotic figures were very rare in the sections examined.

Stage V - Break-up of the Primary Anlage - 11 mm. - 17 weeks.

The head region is well formed. The pharynx is widely open into an open oesophagus. Three gill slits are patent, while the fourth and fifth show signs of rupturing. The four true aortic arches have become complete. The first indications of developing cartilages in this region are evident as rearrangements of the mesodermal cells laterally in the mandibular, hyoid, first true gill arches and in the upper jaw. The copulae of arches I and II are more clearly evident as concentrations of the mesoderm medially, but there is as yet no indication of basibranchials behind the first true gill arch. Muscle is differentiating ventrally in the cranial portion of the lower jaw.

The thyroid of the 17 week embryo is a broken up, ill-defined mass of tissue around the cranial end of the truncus arteriosus. A large mass of the organ, about 40 μ. long, lies ventral to the truncus. Cephalad to this a more diffuse mass of tissue, about 60 μ. long, extends laterally and dorsally around the cranial end of the truncus arteriosus and the vessels branching from it. The more cranial portions of the thyroid complex show an organization into vesicles, the cell boundaries and outlines of which are very indistinct. Most of them seem to contain a fine precipitate of chromophobe material, but in a small number droplets of acidophilic colloidal material may be made out. The caudal portion of the anlage does not differ greatly from that described in

the last two stages. A layer of nuclei surrounds a clearer area of cytoplasm. Cell boundaries are not evident. A few non-follicular clefts may be seen in the central portion of the anlage. In some places the nuclei assume a follicular arrangement with no indication of secretory material, either chromophobic or chromophilic. These follicular walls simply surround a clearer area of cytoplasm as in the early anlage. Mitotic figures are present.

Stage VI - 44 day Sandwich embryos - 11 mm.

The 11 mm. Sandwich embryos are somewhat more advanced in development than Saint John fish of the same length. This would seem to indicate that length alone is not a criterion for the stages of development.

In these embryos all five true gill slits are formed. Developing cartilage is present in all arches except the most caudal one. The basibranchials of gill arches III and IV are indicated although cartilage is developing medially only in the mandible. The entoglossal bone is not yet mapped out. Further differentiation of the heart with a change in its positional relationships has occurred. Reference to figure 5 will show that in this early stage the heart is attached ventrally in the region between the hyoid and third arches. Due to the elongation and forward growth of the lower jaw this organ is now placed at about the level of the fourth arch (fig. 6). Whereas in the early stages the aortic arches originated from a sac-like expansion of the cranial

end of the heart, which we have loosely referred to as the truncus arteriosus, they now arise from a definite ventral aorta which is quite distinct from the truncus arteriosus proper. This change seems to be due to the stretching and elongation of the whole region. The truncus arteriosus has a muscular wall in contradistinction to the thin walled ventral aorta of this stage. It will be seen from figure 7a that this latter channel is still incompletely formed. This is particularly true between aortic arches I and II where channels have not become confluent.

The thyroid tissue has become still further scattered. Figure 7a is a graphic reconstruction of the organ in relation to the ventral aorta. The hyoid arteries have been shown in this figure, but are omitted from the subsequent drawings.

Very little solid undifferentiated thyroid tissue remains. For the most part the cells are being rearranged into the primary follicles. However this process can be followed more readily in the next stage to be described, and will be discussed in detail there. The thyroid tissue of the 44 day Sandwich salmon is often difficult to identify with certainty. Cell boundaries and cytoplasm cannot be made out in these embryonic cells. Except for their slightly larger size and clearer appearance the nuclei are very similar to the surrounding mesoderm. Their arrangement in small spherical masses is, however, quite characteristic.

Many of the primary follicles contain colloid. In such cases their identity is certain. Mitotic figures are numerous in these specimens.

The reconstruction suggests three, more or less distinctly separate, masses of thyroid, one ventral and the other two dorsal to the aorta. Since the ventral anddorso-caudal masses are somewhat lateral in position, in reality they are not isolated. The tissue forms an almost complete line of differentiating follicles between aortic arches I and II, and along the dorsal and lateral walls of the aorta. It will be recalled that the hyoid arteries were primarily attached to what is now the truncus arteriosus, and that the thyroid anlage was first located in the bifurcation of the aorta or the origin of the hyoids. Hence the thyroid stretching from the origin of the hyoids to the truncus arteriosus in this stage has not undergone the migration which might seem to be indicated. This gland, differentiating simultaneously with the ventral aorta, simply becomes stretched out along the elongating vessel. Finally, it should be noted that in all the specimens of this age examined the thyroid tissue was entirely caudal to the basihyoid cartilage.

Stage VII - 51 day Sandwich embryo - 13.5 mm.

The remaining basibranchials have been laid down in the 51 day fish, and fully differentiated cartilage is present in the arches laterally and in the mandible and basi-

hyoid. Cartilage has not yet appeared in the entoglossal portion of the basihyoid, although this structure is indicated as a concentration of mesoderm cranially. The hyoideal muscles and blood vessels occupy the entire space ventrally between the basihyoid and the body wall (fig. 6). Thyroid tissue is now completely cut off from its point of origin at the cranial end of the urohyal. The truncus arteriosus is relatively further caudal at this stage, now being located ventral to the region between arches IV and V. The lymphatics which later assume such an intimate relation with the thyroid gland are becoming prominent as thin walled channels, often containing a few blood corpuscles. At places thyroid follicles are found in rather intimate contact with these vessels. In the 44 day salmon the beginnings of these lymphatics are indicated anteriorly as scattered spaces.

Because of the differentiation of the surrounding mesoderm into connective tissue proper, the thyroid material can be readily recognized in this and in subsequent stages. Figure 7b is a graphic reconstruction of the gland in a 13.5 mm. specimen. The three areas of proliferation suggested in the reconstruction of the 44 day Sandwich fish are evident in this figure. As before these are not in reality as definitely separated as indicated. However since they appear in most of the reconstructions they probably represent more or less distinct areas of growth into which the primary thyroid tissue had been forced by the surrounding structures.

The glandular tissue is made up of primary follicles together with considerable undifferentiated material. Evidence of the processes involved in the morphogenesis and histogenesis of the primary follicles is rather definite. In favorable localities the following processes relative to this genesis may be observed; cellular proliferation as evidenced by the numerous mitotic figures, the arrangement of the nuclei in small solid clumps or spheres, the follicular arrangement of nuclei about an area of finely granular chromophobic material, the arrangement of nuclei about droplets of acidophilic colloidal material. Cellular rearrangement seems always to presage the appearance of the secretory material. Since however the cell outlines are indistinct or absent and the arrangement is not always clear this may not be universally true. From these observations it would seem that the steps in the formation of the primary follicle are, cellular proliferation, arrangement into solid spherules, lumen formation and secretion.

The primary follicles themselves appear as small spherical bodies about 10 to 15 μ. in diameter. They are indefinitely outlined by a single row of oval nuclei. These nuclei measure about 4 to 7 μ., and are of the type already described being relatively clear with one or two large clumps of chromatin. The long axis of the nucleus is parallel to the wall of the follicle, or in other words the cells are of a very low cuboidal or deeply squamous type. A scanty rim of

non-staining cytoplasm can be made out in the more differentiated acini, but cell boundaries are absent. Deeply staining acidophilic colloid fills the acinus except for a narrow shrinkage rim. Mitotic figures, indicating increasing size, are common in the walls of these primary follicles. Although it would be difficult to prove with certainty, budding from the follicular walls of masses of epithelial cells, seems to occur. These buds may be either hollow or solid in nature.

An interesting anomaly was observed in two of the four 51 day specimens examined. Of all the salmon studied only one additional example was found. It will be recalled that all the thyroid material is normally caudal to the basihyoid. In these specimens, however, small isolated areas of thyroid tissue were found anterior to this copula and near the point of origin of the gland (fig. 6). In the 51 day specimens a solid mass of epithelial cells was present. These were very clearly differentiated and marked off from the surrounding connective tissue. In one of these examples it was connected to the pharyngeal epithelium. In the older salmon showing this anomaly, discreet and typical follicles were present. These facts seem to afford additional evidence for the origin of the gland from the hyomandibular region.

Stage VIII - 65 day Sandwich alevin - 15.8 mm.

The entoglossal cartilage is now well differentiated, while the fleshy part of the tongue is making its appearance

around this cartilage from the epithelium and the neighboring mesenchyme. These embryos hatched sometime between 60 and 65 days. At this time the gill filaments are well differentiated. At 51 days they appeared as solid outgrowths with the blood vessels commencing to penetrate them. At 65 days a capillary surrounded by respiratory epithelium extends through the length of the filament. Secondary filaments are not evident until the 86 day stage. The thyroid sinus is well mapped out at this time and in many places the follicular epithelium has come into intimate contact with the endothelium (fig. 9).

A comparison of figures 7b and 7c shows that the thyroid tissue has increased considerably in bulk during this interval. This is particularly true of the mass about aortic arch II. This same mass of tissue which originated in the midline is now rather definitely divided into two lateral portions. This is due to the growth of the basibranchials and the narrowing of the space between them and the ventral aorta (fig. 9). The thyroid gland seems to fit itself into the available space.

The primary follicles have increased somewhat in size, and are now more discreet and definitely differentiated from the surrounding tissue. Otherwise the gland shows essentially the same cytological features as described for the 51 day specimen.

Stage IX - 86 day Sandwich alevin - 22 mm.

All structures of the lower jaw are now well differentiated. The tongue is prominent and teeth are making their appearance. The gill filaments have assumed their adult characters and are decidedly complicated by secondary growths.

The thyroid has grown considerably and assumed in general its adult distribution (fig. 7d). The three areas of growth are evident, while the posterior dorsal portion of the gland has become completely divided and pushed somewhat lateral.

Histologically, the differentiating areas for primary follicles have become relatively few. The well differentiated and enlarged follicles of adult character are more numerous. Masses of pigment are quite common.

Stage X - 32 week St. John salmon fry - 26 to 28 mm.

The embryological study will be concluded with a description of the 26 to 28 mm. Saint John fry (7 weeks after hatching). A comparison of the thyroid reconstruction of this fish (fig. 10) with that of the last stage (fig. 7d) and with subsequent stages (figs. 12 and 13), shows that the organ has practically attained its final area of distribution for the fresh water salmon.

A considerable increase in the bulk of the gland between the 22 mm. and the 28 mm. stages is evident. This increase is most pronounced ventrally and in the dorsocranial portions.

The serial sections show that the position of the

thyroid elements can be readily explained by a consideration of the space available in this region of the throat. The mid longitudinal division of the glandular tissue is due to the very narrow space existing between the triangular basibranchials and the ventral aorta. This space is in many places occupied by transverse connections of the thyroid lymph sinus (fig. 11b). The transverse anterior division of the dorsal mass is caused by the arching of the first aortic arch to the gills. These vessels occupy the space between the branchial cartilages and the body wall. Scattered ventral follicles form the only thyroid tissue in this region (fig. 11a). A second transverse dorsal constriction - midway between aortic arches I and II - is suggested by the reconstruction. This is also noted in the parr thyroid (fig. 12), and seems to be due to the union of the hypobranchial with the basibranchial cartilages in this comparatively narrow region of the throat. The same arrangement of cartilages occurs caudally but there, due to the widening of the area, room remains for thyroid tissue to spread around the aorta. The distribution of this diffuse gland is then dependent upon the available space. Although in the broader sense this distribution is quite uniform, the arrangement does permit of considerable variation in detail.

Histologically the thyroid acini have become well differentiated. Masses of undifferentiated prefollicular tissue are no longer evident. The follicles are well delimited

spherical structures, varying considerably in size up to 40 or 50 μ. in diameter. A single row of cells with prominent round to oval nuclei bound them. A small amount of acidophilic cytoplasm can sometimes be made out between the nuclei, but definite cell boundaries are absent. The epithelium may be classed as low cuboidal. The nuclei at this stage show definite signs of maturity. They are smaller - 4 to 5 μ. in diameter - more spherical in shape, and with more evenly divided chromatin material. In general they are much darker than the large embryonic nuclei with their scattered angular masses of chromatin. The follicles are filled with acidophilic colloid which may be somewhat shrunken from the acinar walls. In places the thyroid follicles are rather compactly united with little or no intervening stromal tissue; but more often they are scattered with the loose connective tissue of the throat region intervening. Pigment masses are common in the neighborhood of the thyroid.

The median hypobranchial and commissural arteries were identified but no branches or twigs could be found entering the thyroid tissue itself. A large lymph sinus, on the other hand, comes into intimate relationship with the thyroid epithelium. In places the union is so close that it is difficult to be certain whether an endothelium is always present (fig. 11). In the 28 mm. fry this huge vessel has attained essentially the distribution which obtains in the adult (fig. 17). Anteriorly it can be traced to a blind ending

beneath the cranial portion of the hyoid complex. No venous connection could be established here in this specimen. Caudally the sinus drains into the system of lymphatics ventral to the pericardium - ventral pericardial sinuses of Allen (1906). At this stage the cranial portion of the sinus - immediately caudal to aortic arch I - is in the form of paired channels with a number of transverse anastomoses. In later stages this portion of the sinus is disposed to the left. Erythrocytes were rarely found in the thyroid sinus of this specimen.

DISCUSSION OF DEVELOPMENT

The generally accepted conception of the development of the teleostean thyroid is contradicted by the above findings. No suggestion of the hollow outpocketing and primary vesicle discussed and figured by Maurer (1886) has been found. The data are more nearly in accord with the brief account given for Ceratodus by Greil (1906),although Gudernatsch (1911) refuted this work in favor of Maurer's. Greil described a solid anlage which became vesicular before separation from the pharynx. In this latter point his findings differ from mine. In the Atlantic salmon the thyroid appears as a diffuse mass of entodermal cells proliferated from the mid-ventral region of the floor of the pharynx. This mass soon becomes definitely outlined and nodular in form with the nuclei arranged around the periphery, but at no time is there any evidence of a vesicle. Apparently the anlage of the

teleostean gland is solid as is that of the elasmobranch (Norris, 1918b) and the ganoid (Hill, 1935). This course of events seems more logical since the majority of the organs in teleosts develop from solid rather than vesicular anlagen (Vogt, 1842; Wilson, 1889). Moreover, solid anlagen have been reported for other organs of the Atlantic Salmon - the swimbladder (Hoar, 1937) and the pituitary (Woodman, 1939). The thyroid seems to appear at only one point on the floor of the pharynx. In this our findings agree with those of Maurer. Hill (1935) in his studies of Amia sometimes found small accessory masses.

It is shown clearly in figure 2 that the thyroid makes its appearance at the caudal border of the junction of the hyoid and mandibular regions. Former descriptions have placed the embryonic center somewhat caudal to this. Maurer (1886) states that the anlage in the trout arises in the crotch of the hyoid arteries and illustrates it in a locality similar to that which we have stressed. However, he does not state definitely its relation to the gill pouches. Gudernatsch (1911), on the other hand, places the embryonic center between the first and second gill pockets or the adult region of the aortic bifurcation. This is presumably behind the hyoid complex and does not agree with my findings. Norris (1918b), in the dogfish, finds the organ to arise caudal to the ventral extremeties of the first two pairs of gill pouches. Hill (1935) stresses the same region although

he cannot be certain of the locality. In the salmon the gland arises somewhat cranial to this position. It is of interest that Platt (1896) finds the thyroid anlage of Necturus to appear opposite the hyomandibular pocket rather than in the region of the second branchial as described for other amphibians - Triton and Siredon - by Maurer (1888).

Since the degree of development and the length of fish of different ages vary so markedly with the temperature of the water in which the eggs are incubated, it is illogical to state without reservation that the anlage makes its appearance in embryos of any given length or age. It seems better to describe the time of origin in relation to the state of development of surrounding structures in the lower jaw.

In the trout, Maurer (1886) found that the thyroid appeared after the following degree of differentiation had been attained; closed medullary tube, primary brain vesicles and lens of the eye formed, mouth opening present, hyoid arch heavily mapped out and first gill slit formed, four true gill arches indicated as ventral swellings separated by furrows, S-shaped heart and paired hyoid arteries present and before the four true gill arteries or any cartilage had appeared. The present findings are generally similar to these although they seem to indicate that the gland arises comparatively earlier in the salmon. In the Atlantic salmon only three true gill arches are indicated at the time of the appearance of the thyroid and it seems inaccurate to say that the mouth

is open when the pharynx is still solid and neither Meckel's cartilage nor the maxillary process have yet appeared. The vascular relationships are similar in both salmon and trout at the time in question. In view of the present interest in the interrelations of the pituitary and thyroid glands it is of interest that the hypophysis of the salmon makes its appearance during the same week as does the thyroid (Woodman, 1939).

Maurer (1886) states that the thyroid anlage of the trout remains attached to the pharynx for only one day. Again, comparisons are not pertinent without knowing the temperature conditions under which the material developed. It can only be said that in Atlantic salmon developing under normal conditions the solid anlage remains attached for about 15 days. The difficulty encountered in tracing the origin of the gland in the Sandwich material is probably due to the brief attachment of the gland and the general similarity of the embryonic cells of the different organs. Some writers have stressed the mechanical pull of the blood vessels as being of importance in the separation of the gland from the oral epithelium; this pull at times causing a definite dimple or pit in the floor of the pharynx (Hill, 1935). Maurer (1886) finds that the primary anlage comes to lie in the aortic crotch and then far ventral and under the arterial trunk caudally. He stresses the important influence of the blood vessels on the migration of the follicles.

Gudernatsch (1911) states that they form a substratum along which the follicles migrate. Our interpretation would not suggest any peculiar importance of the blood vessels in the early morphogenesis of the gland. The change in the position of the anlage is relative, due to the forward growth of the lower jaw and the development of its medial cartilages. The latter factor forces the anlage ventral, and the former changes its relative position caudal. At first the anlage lies at the cranial end of the sac-like arterial end of the heart. As the latter elongates into the ventral aorta and truncus arteriosus, the thyroid tissue, growing rapidly at the same time, spreads out around it. A portion of the caudal end of the anlage early comes to lie beneath the cranial end of the developing aorta, but at no time can it be said that the anlage has migrated ventral to the aorta or that the main mass of the gland lies ventral to this structure as was stressed by Maurer in 1886. Moreover, no groove or pit is found in the salmon to indicate that the anlage has been pulled loose from the floor of the pharynx. The developing thyroid may be elongated in the direction of its point of origin to form the suggestion of a thyreoglossal duct, but this is due to the rapid forward growth of the lower jaw rather than any pull from behind the truncus arteriosus.

With further growth the thyroid tissue unlimited by any capsule spreads out on all sides of the aorta. Three more

or less distinct areas can be described, one lying ventral and the other two dorsal to the ventral aorta. The dorsal masses are separated by the first aortic arch.

The histogenesis of the teleostean thyroid differs considerably from that of the elasmobranchs and higher vertebrates as set forth by Norris (1916, 1918). The process seems much simpler here. Florentin (1932) working on several species of teleosts and Hill (1935) studying Amia calva have described the formation of vesicles through the budding of the primary anlage. Ramsay (1938) has described a similar course of events in the cat where the thyroid seems to arise in a very primitive manner. Maurer (1886), in the trout, described the formation of solid buds on the primary vesicle which soon acquired a lumen and were pinched off.

From this study it is concluded that the following steps represent the course followed in the differentiation of the primary thyroid follicle; cellular proliferation, rearrangement of cells into solid spherules, cavity formation, secretion of material first probably chromophobic and later chromophilic. The process does not differ greatly from the later stages in the classical descriptions of E. H. Norris. The transformation of the primary anlage into a system of bars and plates is, however, never evident. It is of interest however that in several cases small non-follicular cavities of the type described by Norris (1918b) are recognizable. These are always very small and never increase to the extent

of converting the structure into bars of tissue.

The process described by Bradway (1929) in which primary follicles form through the secretion and coalescence of droplets of chromophobic colloid may well occur, but in many cases at least solid spheres of cells seem to arise before the appearance of secretory material.

Norris (1916) has described the formation of secondary from primary follicles by three methods, solid buds, hollow buds, and by constriction of the parent follicle. Definite evidence of the first two processes is afforded by the salmon material. Since the third method is a modification of the second it may very well occur also.

The rearrangement of cells into solid spherules was first observed in young salmon of 9 mm., when the pharynx is in the process of opening, the second gill slit forming and aortic arches III and IV have become complete. Vesicles were noted in the Saint John salmon of 11 mm., in which there are three patent gill slits, four complete aortic arches and when the first indication of developing cartilage is present. In slightly more differentiated embryos (11 mm. Sandwich fish) in which all five gill slits are formed and the different cartilages of the lower jaw recognizable, acidophilic colloid was found in the vesicles. From the conclusions of Hogben and Crew (1923) it seems possible that the gland commences to function at this time. In contrast to the higher vertebrates colloid appears very early in the fish

thyroid.

Maurer (1886) described the formation of a lightly refractive material in the lumen of the primary anlage. There is a clearer central area in the anlage of the salmon thyroid, but this is very definitely cellular in nature and not secretory material. The budding of the anlage described by Maurer occurs at approximately the same time as the formation of primary follicles in the Atlantic salmon but the course of the histogenesis is quite different.

GROSS AND MICROSCOPIC ANATOMY

Literature

The term "gland" is not, strictly speaking, applicable to the thyroid of the teleosts. In the higher vertebrates and in the elasmobranch fishes thyroid tissue is found in discreet, more or less definitely encapsulated masses but in the teleosts the thyroid consists of numerous isopotent units, the follicles, scattered very diffusely over a comparatively wide area. Although anatomically there is this distinction it is of no physiological importance and the term "gland" is loosely applied to the thyroid of teleosts as well as to that of the other vertebrates.

Among different species of teleosts there is the widest possible variation in the compactness of the thyroid tissue. Variations are found in closely related species and even from time to time in the life of an individual of a given species

(Gudernatsch, 1911; Burne, 1926). The thyroid of the swordfish, Xiphias gladius L., most nearly approaches the condition of a discrete gland as found in higher forms. In this species the organ consists of four definite masses, which in their compactness and arrangement are very similar to the thyroid of the elasmobranchs or of the higher vertebrates (Addison and Richter, 1932).

The extent of distribution of the teleostean thyroid has been differently defined by various authors. In Amiurus the thyroid extends cranially to the first pair of gill arches, and caudally a short distance behind the third and fourth arches (MacKenzie, 1884). In the trout, Maurer (1886) found essentially the same distribution, stating that the gland extends cephalad not further than the bifurcation of the aorta and caudad not behind the origin of the fourth gill arch. Maurer states repeatedly that the main mass of thyroid tissue lies ventral to the aorta. Gudernatsch (1911) insists that the boundaries emphasized by the two above workers are much too narrow and that the bulk of the organ lies dorsal to the ventral aorta. In some cases (e.g. the eel) the greatest quantity of thyroid tissue lies cranial to the bifurcation of the first aortic arch although it is only rarely that the caudal limit is behind the last arch. He states that the follicles are most numerous at the origin of the second gill arteries, and fewest in the region of the third and fourth. Moreover, except in Fundulus, the numbers of

follicles lying lateral to the aorta are always less than those above or below it. In Anguilla vulgaris the thyroid tissue is found rostral to the bifurcation of the first aortic arch and just beneath the basihyal (von Hagen, 1936). In Xiphias gladius, two masses of thyroid are found between the first and second gill arteries, and two masses between the second and the common origin of the third and fourth (Addison and Richter, 1932). In Lophius piscatorius, thyroid follicles are found as far cranially as the symphysis of the hyoid (Burne, 1926). From these various findings it might be concluded that the teleostean thyroid is distributed from the basihyoid cartilage to a short distance caudal to the origin of the third and fourth gill arteries, although it seems probable from the nature of the organ that there are definite individual differences as well as species variations. Dorsally the thyroid is limited by the basibranchial bones and ventrally by the paired musculus sternohyoideus (Gudernatsch, 1911).

Because of the diffuse arrangement of the teleostean thyroid a consideration of its histology is reduced to a study of the individual follicle. The arrangement of acini, a question highly debated in considerations of the mammalian thyroid, does not enter into this problem. For the sake of comparison, however, it may be said that the reconstructions of Reinhoff (1929) have shown the parenchymatous tissue of the mammalian thyroid to consist of plates, bars, and bands

separated by tissue of mesenchymal origin but nevertheless always connected with one another so that there are no isolated acini or groups of acini. That aggregations of follicles are separated by connective tissue bands to form lobules is no longer accepted. Some few workers have described a more or less precise distribution of follicles in the teleostean thyroid. Maurer (1886) found that the vesicles assumed a lobular arrangement after a certain age. Burne (1926) describes them as clumped together in oblong masses, or like chaplets of beads as though they had budded off from a single primary vesicle. The consensus, however, is that there is no definite order to the arrangement of the follicles in this group of vertebrates.

The histological unit of the thyroid gland is the follicle. It has the same general character in all vertebrates. However the details of its size, shape, and structure, have been the subjects of numerous investigations. Much of the apparent disagreement is now seen to be the result of constant change in the follicle due to its activity. The thyroid is one of the most labile of organs, changing not only under the influence of prolonged stimuli, such as metamorphosis, seasonal changes in temperature, etc., but also from time to time during the day (Williams, 1937). Thus from the strictly anatomical standpoint, on the basis of wax reconstructions (Wilson, 1927; Reinhoff, 1929), maceration experiments (Jackson, 1931), and microscopic studies (Key, 1925), investi-

gators have placed the size of the normal follicle all the way from 20 up to 1294 μ. Tissue cultures have recently shown that the follicle goes through a definite sequence of size variations every 19 to 21 hours (Williams, 1937). The relation of follicle size to the physiological activity of the gland is well known. Again the shape of the follicle shows wide variations. In the resting thyroid the small acini tend to be spherical while the larger ones may be oblong, triangular, or cuboidal, but always with blunted angles (Reinhoff, 1929; Wilson, 1927; Jackson, 1931). In the active gland, on the other hand, the follicles become much infolded and complicated in form (Means, 1937). Although budding from the wall of the follicle probably occurs during growth (Norris, 1918), reconstructions of the mammalian thyroid show that this does not take place in the adult gland and also that there is no undifferentiated thyroid tissue between the acini (Wilson, 1927). Moreover, budding does not occur in tissue cultures (Williams, 1939).

The wall of the follicle consists of a simple epithelial layer resting on a delicate connective tissue base. The size and shape of the cells forming this layer vary with the physiological state of the organ. Marine (1911 to 1935) maintains that the epithelium of the normally resting thyroid follicle is at most cuboidal, and that a high cuboidal or columnar epithelium always indicates activity. This is the accepted view at the present time. Two types of cells, the

chief and Langendorff cells, have been described as forming this epithelium. These two types are found in all classes of vertebrates, but the consensus at present is that they represent different phases in the secretory activity of the normal cell (Marine, 1928), or that the cells of Langendorff are dead and dying chief cells (Cowdry, 1934; Maximow, 1938; Rice, 1938, etc.).

The thyroid acini, in the resting condition, are completely filled with colloid. Clear vacuoles of recently secreted material may be present at the periphery but any extensive space is due to shrinkage. In the resting gland the colloidal material is acidophilic. It becomes basophilic in the active glands (Hewer, 1927), and may disappear entirely in extreme degrees of hyperplasia (Means, 1937). Erythrocytes, leucocytes and desquamated epithelial cells within the colloid have been described repeatedly, but Williams (1937) can find no evidence of any inclusions within the living follicles.

In mammals the thyroid units are supported by a delicate reticular tissue (Maximow, 1938; Ramsay, 1938). In teleosts the supporting element is the common connective tissue of the head and does not represent a true interstitial tissue as we find it in the more aggregated glands. Addison and Richter (1932) have described very fine elastic fibers in the supporting tissue of the swordfish thyroid, and Gudernatsch (1911) finds smooth muscle fibers in the connective tissue about the

follicles of Salvelinus and Sarda. These muscle fibers are said to be most numerous in the tissue below the ventral aorta. Aside from these observations the precise nature of the "interstitial" tissue does not seem to have been described. Interfollicular glandular cells and lymphocytes are frequently described in the thyroids of higher forms. The former are now considered to represent tangential sections of follicles, although some consider that the term is still useful for descriptive purposes (Rice, 1938). Scattered foci of lymphocytes are of normal occurrence in the mammalian thyroid, and Maurer (1886) has described nodules of these in the thyroid of an old carp. Pigment masses are frequently found in the connective tissue surrounding the follicles of the thyroid of teleosts. Gudernatsch (1911) suggests that these are of haematogenic origin.

The thyroid gland of teleosts receives blood from a special thyroid artery. This arises as a dorsal branch of the hypobranchial artery just caudal to the point where the latter is formed from the union of the right and left fourth commissural arteries. These commissural arteries originate from the second efferent branchial arteries and unite in the median line below the thyroid and the aorta to form the hypobranchial. The thyroid artery immediately enters the thyroid tissue (Sylvester, 1905). The most cranial portions of the thyroid may receive their blood supply from a special capillary net derived from the first aortic arch, the arteria

thyreo-spiracularis (Gudernatsch, 1911). A thyroid vein collects blood from this organ and after receiving tributaries from the muscle underneath the ventral aorta empties along with the subclavian into the sinus venosus (Sylvester, 1905; Gudernatsch, 1911). Burne, (1926)describes an "anterior" and a "posterior" thyroid vein, the former entering the main trunk of the subclavian and the latter joining the subclavian at a more caudal level. The blood supply of the elasmobranch thyroid has been described in detail by Ferguson (1911).

Capillaries form a rich plexus about each individual follicle. Wilson (1927) has made detailed reconstructions of these for the mammalian thyroid. A similar network has been described for the elasmobranchs (Ferguson, 1911) and for the teleosts (Maurer, 1886; Gudernatsch, 1911). In Lophius, Burne (1926) finds this plexus to be much more open than that in the higher vertebrates and to consist of large almost lacunar spaces. Surrounding the follicles, Florentin (1927) describes very large capillaries in intimate contact with the epithelium.

The lymphatics of the thyroid have been the subject of numerous investigations. In the mammals the gland is richly provided with vessels arising in the interfollicular connective tissue and continuing into larger trunks to form a dense plexus beneath the capsule. However, some workers stress a much more complicated arrangement of lymphatics and

parenchymatous tissue. Although the theories of Williamson and Pearse (1923, 1926) have been discredited it seems worth mentioning that they visualized the morphological unit of the thyroid gland as a lymphatic sinusoid containing coiled columns of epithelium enmeshed in a basketwork of specialized blood vessels. In the cat, Ramsay (1938) finds a more intimate relation of thyroid follicles and lymphatics than is true for the mammals in general. In this form the thyroid is surrounded by a large lymph sac, each follicle making broad contact with the lymphatic endothelium. Ramsay (1938) points out the resemblance of this arrangement to that of lower forms. It might also be mentioned that Anderson (1894) has described a flagellated epithelium in the thyroid follicles of a 4 day old kitten. Cowdry (1921) has described such an epithelium in the dogfish, Mustulus canis.

Baber (1881), one of the earliest workers on the fish thyroid, could findno evidence of lymphatics in the gland of the skate and the conger eel. Since his time, however, they have been demonstrated both in the elasmobranchs and the teleosts, although the relationship of lymphatics to acini in these two groups is considered by some to be very different (Florentin, 1927). In the dogfish, Ferguson (1911) describes an elaborate thyroid sinus consisting of an intricate network of veins and lymphatics. This system is connected laterally with the hyoid sinus and in the median line spreads over the ventral surface of the gland. The lymphatic ramifi-

cations spread out in the thyroid tissue; their endothelium forming an intimate contact with the epithelium of the follicles. In the trout, Gudernatsch (1911) describes certain large cavities about the ventral aorta. Two dorsal channels are found to be constant and in some places these surround the aorta more or less completely. He believes these to be lymphatic vessels, and comments on their intimate relationship with the thyroid follicles. In places, he states, the smallest of the lymphatics loose their endothelium and the epithelium of the follicle is bathed directly in lymph. Allen (1906) in his studies of the lymphatics of Scorphoenichthys describes a thyroid lymph vessel lying dorsal to the thyroid gland. This vessel is a branch of the anterior division of the ventral pericardial sinus. In Lophius piscatorius Burne (1926) has found a peculiar arrangement of thyroid tissue and lymphatics. The thyroid is occupied by or lies around a large lymph sinus which is continuous with the ventral superficial system of lymphatics. Burne emphasizes the peculiarity of this arrangement, stating that the thyroid in other forms is surrounded by lymph vessels. The relationship of endothelium and epithelium is very intimate in Lophius. From these studies it would seem that a system of lymphatics, intimately associated with the epithelium of the gland, is prominent in the thyroid tissue of the teleosts. Except for the peculiar sinus discussed by Burne (1926) the teleostean lymphatics have not been figured

or described in detail.

The histological relationship of the thyroid epithelium and the endothelium of the vascular elements has been subject to considerable discussion. At most a delicate layer of connective tissue is believed to exist between these two layers. Some workers have failed to identify this (Addison and Richter, 1932), while others go so far as to state that the follicular epithelium is bathed directly by the lymph (Gudernatsch, 1911). Florentin (1927) finds that the vascularity is very different in selachians and teleosts. In the former group both blood and lymph capillaries are found around the follicles, but the lymphatics play the predominant role in the removal of secretory material. In the teleosts, onthe other hand, he believes that vascularization is entirely by means of large blood capillaries. All writers agree that there is an intricate network of vascular channels around the individual follicles, but there seems to be less agreement as to the exact nature of this.

The innervation of the thyroid gland of fishes has not been investigated. In the mammals it is supplied by a rich plexus of non-medullated nerves which reach the gland along the blood vessels and indirectly through the superior laryngeal and recurrent laryngeal nerves. Perifollicular plexuses completely surround all follicles. The terminal portions are short with straight or curved knob-like enlargements which end against the basal portions of the cell, but

never penetrate between the cells. Only a few cells in each follicle can be demonstrated to come into relation with the nerve endings (Marine, 1928). Although some of the earlier workers have reported ganglion cells in the thyroid (Anderson, 1894), these have now been proven to be absent (Marine, 1928). Anatomical evidence indicates the presence of both vasomotor and secretory nerves in the thyroid, but physiologists have decided against the nervous control of thyroid secretion (Marine, 1928; Friedgood and Cannon, 1936).

Distribution of Thyroid Tissue

Figures 12, 13, 14, and 15, show the distribution of the thyroid of the adult salmon. The photomicrographs show the diffuse nature of the gland which might be thought to be rather massive in nature from figures 12 and 13 alone. The graphic reconstructions were made from parr and smolt thyroids. Although there is an increase in the amount of tissue with age, these diagrams show that the general area occupied by the gland is the same, even in the large fish. In the salmon the follicles never become spread out and scattered into isolated groups as they do in Lophius (Burne, 1926).

The thyroid gland of the Atlantic salmon extends cranially beneath the caudal part of the first basibranchial. It is not usually found cranial to this. However it will be recalled that the organ originates anterior to the hyoid complex, and a few of the specimens studied show an anoma-

lous mass of thyroid material in this region (fig. 13). This is found beneath the cranial part of the hyoid complex and consists of several small follicles containing typical colloidal material. In the caudal direction the thyroid tissue extends a short distance behind the common origin of the third and fourth aortic arches, over the cranial portion of the bulbous aorticus. This distribution is essentially the same as that given by Gudernatsch (1911) for the trout; and, as he has pointed out, is considerably greater in extent than was found by the earlier workers. The greatest mass of thyroid tissue in the salmon lies around the second branchial arch. The condition is similar in the trout (Gudernatsch, 1911) but in the swordfish and eel the bulk of the organ lies at the cephalic end of the ventral aorta (Addison and Richter, 1932; von Hagen, 1936). There seems to be considerable variation in this respect in the different species of fish. An examination of the photomicrographs (figs. 14 and 15) shows that the quantity of thyroid tissue laterally is always less than the quantity dorsally and ventrally. Moreover the main mass of the organ lies dorsal to the ventral aorta. Again the findings substantiate those of Gudernatsch (1911) rather than Maurer (1886).

From dissections it might appear that the thyroid is limited dorsally by the basibranchials and ventrally by the musculus sternohyoideus, as has been stated by Gudernatsch (1911). Microscopically, however, the bulk of the tissue is

found to lie lateral to the basibranchials. Ventrally the thyroid never extends to the sternohyoid muscle, but is separated from the hyoideal musculature by considerable connective tissue and an elongated constricted region of the isthmus of the throat (fig. 15). It is difficult to place exact boundaries to such a diffuse organ. It seems to occupy whatever space is available around the ventral aorta. This becomes more evident as the gland increases in size (fig. 16).

Three more or less distinct masses of tissue were found in the thyroid of the embryos. The gland of the adult is divided into corresponding masses. The cause of this division is seen to be the same in the two stages. In the reconstructions the cranial dorsal division is much less pronounced, since scattered follicles pass over the first arch. The sections, however, show that the tissue is very scanty in this region. Certain early writers state that the teleostean thyroid is a paired gland (Wiedersheim, 1909) or a partially paired gland (Maurer, 1886). Gudernatsch (1911) denies this stating that the organ is unpaired. Although in such a diffuse and irregular structure the distinction is of little significance, the diagrams and photographs indicate that the tissue tends to be divided into two portions by the very narrow region between the basibranchials and the ventral aorta (fig. 15). Scattered follicles appear in this region (figs. 14 and 15).

The details of the distribution described above vary

from time to time during the life of the fish. These changes will be discussed fully in another section.

Histology

The histological details of the thyroid follicle vary with the activities and the age of the fish. These will be discussed in connection with the histophysiology of the gland. Here, only the more general characters of the acinus will be described. The outstanding feature of the epithelium is the nuclei. Cytoplasm is scanty and the cell membranes are rarely evident. The cytoplasm, when apparent, is in the form of a continuous acidophilic ring containing numerous nuclei. Only in the more active thyroids are the individual cells indicated, and even the best of these never have the clear-cut characteristics and the quantity of cytoplasm seen in the cells of the mammalian thyroid. The finely divided chromatin material of the nuclei stains deeply. Nuclear shape varies with the condition of the gland. The so-called Langendorff cells with their dense and pycnotic nuclei are frequently found in the thyroids of the larger salmon, 70 to 100 cm. fish, but are rare in the glands of parr and smolt. The only form of basement membrane present is a very delicate layer of connective tissue. At times this seems to be absent and the epithelium appears to rest directly on the endothelium of the lymphatics. Erythrocytes are often found within the lumen of the follicles (fig. 21). There seems no reason to suppose, however, that these are of

normal occurrence. They are probably forced through the endothelium and the epithelium by pressure involved in killing the animal, or by the preparation of the section. I have found no evidence of their degeneration within the colloid as has been described by Baber (1881).

The thyroid follicles are supported by the connective tissue of the throat region. This tissue is described as a loose connective tissue; according to Addison and Richter (1932) containing scattered elastic fibers and small fat cells. In routinely prepared sections of this region the connective tissue appears as a very loose and delicate fibrous network containing numerous clear spaces representing the fat vacuoles of adipose cells (figs. 14 and 15). In certain places, especially in older salmon, the thyroid tissue is almost completely surrounded by adipose tissue. Osmic acid preparations show the fat cells to be of various sizes and quite numerous. When blackened with this reagent they have a peculiar vacuolated appearance not seen in the adipose tissue of higher animals. Although these vacuoles may appear at any point in the cell they are particularly numerous at the periphery. Some cells have so many of these that only a black framework remains in the prepared specimen. The fibrous connective tissue appears to be reticular in arrangement. Verhoff's stain gives no indication of elastic fibers. On the other hand there is some evidence that the fibers may be argyrophilic although this could not be es-

tablished as fact. In the larger and more compact glands there is very little connective tissue between the individual follicles. Fatty reticular tissue is, however, prominent between and around the groups of follicles.

Smooth muscle fibers are not present in connection with the thyroid follicles of the Atlantic salmon. In this respect it differs from the trout (Gudernatsch, 1911).

Irregular masses of dark brown or black pigment are often found in the region of the thyroid (fig. 20). These are particularly prominent on the outer border of the ventral aorta, between this and the thyroid or the lymph sinuses. These masses seem to be relatively more numerous in younger individuals. They have the characteristics of very large and dense melanophores. There is no indication that they are of hematogeneous origin as Gudernatsch (1911) suggested. One might expect to find small quantities of hematoidin and hemosiderin in a region containing so many thin walled vascular channels. However, these are certainly not the pigments so prominent in the thyroid region of the younger salmon.

Lymphocytic foci are not present in connection with the teleostean thyroid, nor do there seem to be any areas of undifferentiated epithelium in the glands of the larger salmon.

Vascularity

The hypobranchial and commissural arteries have been identified and plotted on the diagram of figure 17. Figure 15 shows the hypobranchial artery in relation to the surrounding structures. Two of the specimens examined showed an interesting anomaly. In these only one of the commissural arteries, the left, was present. Although these arteries were followed microscopically throughout their length, the thyroid artery, supposed to arise from the hypobranchial, was not identified. Branches were traced from the hypobranchial into the muscles of the throat isthmus. If present, the thyroid artery of the salmon must be very small and insignificant. It is, however, quite possible that small twigs entering the ventral thyroid masses were overlooked. It can only be said that this arterial supply is not prominent in salmon as large as 15.4 cm. No arterial supply from the first arch was found.

The thyroid veins described by Sylvester (1905) and others could not be identified although the subclavians were traced with ease from the sinus venosus into the pectoral fins.

The prominent vascular channel in this region is the immense thyroid lymph sinus. This has been figured diagrammatically in figure 17, although a two dimensional diagram gives little idea of its intricate ramifications and size. The photographs in figures 14 and 15 will aid in a visuali-

zation of its complicated form and intimate relationship to the thyroid follicles.

In a 28 mm. salmon fry this sinus was traced to a blind end cranially beneath the basihyoid and between the hypohyoid cartilages. Caudally it breaks up into scattered channels above the pericardium and in the muscle of the isthmus of the throat. Burne (1926) states that the thyroid sinus in Lophius is continuous cranially with the inferior jugular veins. Indications of such connections are found in the salmon. The three small branches in the upper part of figure 17 probably represent these. As corroborative evidence for such connections it is found that erythrocytes are much more numerous in the cranial portions of the sinus. This seems to indicate that in the killing and fixation of the animal, blood is forced through the valves into the lymphatics in considerable quantities. It should be remembered, however, that a certain number of red blood corpuscles are of normal occurrence in the lymphatics of fishes (McClure, 1915).

Figure 17 shows that the main channel of the sinus extends dorsal to the ventral aorta and throughout the entire length of this structure. A broad expansion of this occurring in the region just cephalad to aortic arch II extends caudally behind the common origin of arches III and IV. This broad posterior expansion coincides with the region of the largest mass of thyroid tissue (fig. 13). A somewhat

smaller channel is found on the ventral surface of the aorta. This arises from the dorsal channel cranial to the first aortic arch and extending posteriorly forms numerous intercommunications with lateral expansions of the main dorsal vessel (fig. 15). These lateral communications are particularly numerous in the region of, and just caudal to, the second aortic arch (fig. 17); again the most extensive region of the thyroid development (fig. 13). In places these lateral expansions become very prominent (figs. 14d and 15d).

The thyroid lymph sinus develops in the embryo through the coalescence of numerous isolated channels (figs. 8 and 9). Although its development has not been traced in detail it appears to be a paired system in younger individuals, later becoming shifted to the left in the cranial regions and forming cross-communications caudally. The paired condition of younger salmon seems to resemble that in the trout (Gudernatsch, 1911).

The relationship of the lymphatics and the thyroid tissue is most intimate. The lymphatics form the prominent vascular system in the salmon thyroid and probably are of great importance in the removal of the colloid. As evidence of this, colloidal material of the type found in the follicles is often seen in the lymphatics of the more active glands (fig. 18). Other writers have noted the same thing (Gudernatsch, 1911; Addison and Richter, 1932). The present data do not corroborate the findings of Florentin (1927) who

believes that the teleostean thyroid is vascularized only by blood capillaries and in this differs markedly from the selachian organ. The capillary network described by many writers does not seem prominent and it is suggested that the large lacunar capillaries described by Florentin (1927) are lymphatic in nature. As already mentioned the presence of erythrocytes in the vessels of fishes does not prove that they are blood channels. In the killing of the large individuals, head injuries are to be expected. These probably force more erythrocytes into the lymph vessels than are of normal occurrence there. Furthermore, red blood corpuscles are very rare in the channels of young individuals which can be placed directly in the fixative.

In the small fish the large lacunar spaces simply make broad contact with the scattered and isolated follicles (figs. 11 and 14). In larger salmon, smolt and adult, ramifications of these main channels spread around the individual follicles. The lymphatics thus formed between the acini seem to be very large and lake-like, as suggested by Florentin (1927) for the blood capillaries. In the larger specimens, with lymphatics greatly injected with erythrocytes, the follicles appear to be floating in a lake of blood. In many places the epithelium seems to be in direct contact with the blood without any evidence of an endothelium. The latter, however, is always found in the less massive glands and is probably always present. Connective tissue between the endo-

thelium and epithelium is scanty and in many cases apparently lacking. That the vascular plexus around the follicles of the large glands (fig. 21) is lymphatic in nature seems reasonably certain. In many places expansions of the main sinus can be traced between the follicles. These findings are in contrast to the condition in Lophius where lymphatics never invade the perifollicular tissue (Burne, 1926).

Innervation

Attempts to demonstrate nerve and nerve endings by the pyridin silver methods were unsuccessful.

HISTOPHYSIOLOGY

Changes in the physiological activity of the thyroid can be followed histologically with considerable precision. Anatomical alterations of this organ have been associated with many physiological reactions in different animals. Thus, Abbott and Prendergast (1934) in a study of laboratory and wild animals, found that hyperplastic glands were the rule among young individuals and that these were physiological and not pathological. Cooper (1925) has described the following series of changes in the human thyroid gland during the life cycle. The epithelial cells become active in late fetal life, colloid being secreted and stored in the follicles. Vesicle formation and colloid secretion increase until birth. After this event the gland rests a few weeks using up the

stored colloid. It then resumes its activity, and remains active throughout childhood, with a small reserve of colloid always present. At puberty the gland shows its greatest activity. After this, colloid storage again becomes marked, and the gland remains comparatively inactive throughout adult life. With the onset of old age the organ decreases in size and shows definite degenerative changes. Marine and Lenhart (1911) have given a detailed account of these senile atrophies. They find the senile thyroid to be much smaller and firmer due to epithelial and colloid loss, together with an increase in the stroma and sclerosis of the blood vessels often with calcification.

Besides these alterations resulting from the normal activities of the animal, certain extraneous factors have been found to influence the thyroid in a physiological manner. MacKenzie (1903) and Zeckwer (1932) have demonstrated the effects of diet upon the thyroid glands of mammals. Marine and Lenhart (1914) have found similar effects in brook trout. Riddle (1927) has correlated changes in the thyroid of farm animals with temperature. Low temperatures are known to increase thyroid activity in experimental animals (Ludford and Cramer, 1928; Kuschinsky, 1935; Baliff, 1938). Thus it seems that the thyroid gland is played upon by many factors and that it may show widely differing pictures under quite normal conditions.

Although the histophysiology of the thyroid has been

studied in a wide variety of animals the fishes as a group have received very little attention. Marine and Lenhart (1914) have shown that the so-called "goiter" of brook-trout has a dietary basis. Murr (1928) and von Hagen (1936) have related certain changes in the thyroid of the eel to its metamorphosis. Horton (1934) obtained negative evidence in his attempts to relate activities of the thyroid to metamorphosis in the lamprey. Lieber (1936) has described seasonal changes in the thyroid of Misgurnus fossilis L. These few investigations seem to have been the only studies of this nature in fishes.

The physiology of the thyroid gland of the Atlantic salmon has not been investigated. This form has a varied life history and might be expected to show some interesting physiological changes. Hatched in the river the young salmon feeds there for from 1 to 5 years and then, after undergoing a distinct metamorphosis, migrates to the sea. After a 2 or 3 year period of very rapid growth in the salt water the salmon returns to the fresh waters of some river on its spawning journey.

Before studying the thyroid gland in relation to this varied life history, the criteria for distinguishing changes in the functional activity of the organ will be summarized. With the onset of activity the colloid decreases both in quantity and in intensity of staining reaction, colloid vacuoles become numerous, the epithelial walls collapse, the

follicles become star shaped, and the cells become enlarged, swollen, filled with secretion vacuoles and contain a much enlarged and more active Golgi apparatus (Uhlenhuth, 1937). The mitochondria increase in size and number and the gland becomes much more vascular (Severinghaus, 1933). Columnar epithelium with the tufting of follicles is a sign of hyperplasia (Abbott and Prendergast, 1934). Acidophilic colloid is typical of resting glands and basophilic colloid of highly active ones (Hewer, 1927). As already explained, changes in the mitochondria and Golgi apparatus could not be followed in this material. With these exceptions the above criteria for differing degrees of thyroid activity have been relied upon.

Seasonal Changes

Seasonal variations in thyroid activity have been demonstrated in two different species of teleosts. Lieber (1936) has followed the changes in the thyroid of Misgurnus fossilis L. She finds the activity to be greatly reduced from October to the end of March. Marked activity occurs in April but decreases in June with the sexual maturation of the fish. Following spawning the thyroid again becomes active, but its activity declines in September, and the organ remains passive during the winter months. von Hagen (1936) discusses a somewhat similar series of changes in the thyroid of the eel.

The seasonal activities of the Atlantic salmon are also correlated with changes in the thyroid gland. Because of the availability of the material, salmon parr have been used for

the majority of these studies. Since it is impracticable to collect salmon during the winter months, the samples used extend only from June 11th to November 16th.

Throughout the greater part of this period the thyroid tissue is in a mild state of activity. The follicles are small, spherical and of a uniform size. The epithelium is cuboidal or low cuboidal in type with the individual cells usually poorly delimited. The nuclei are spherical in the follicles with a cuboidal epithelium, and oval in the low cuboidal cells. Rarely do the cells assume a high cuboidal form with the long axis of the oval nucleus perpendicular to the wall of the acinus. Langendorff cells are not evident. The follicles are filled with a slightly acidophilic colloid. Clear vacuoles are often seen at the periphery of the colloid. The follicles are scattered with one or two of their surfaces making broad contact with the lymphatics. The most pronounced variations from this general picture are due to the heightening of activity during the early spring and its decline inthe late fall. These changes will now be followed in detail.

Colloid is completely absent from the thyroid follicles of parr collected in the spring of their second or third year (6 to 10 cm. fish). The follicles of these fish vary from 0.1 to 0.5 mm. in diameter, and are bounded by a cuboidal epithelium which shows no evidence of tufting. This is the condition shown by the fish collected on June 11th.

By the first week of July the follicles have become filled with a finely granular and slightly acidophilic colloid. The cuboidal or high cuboidal cells have the characteristics already described. The thyroids collected during October and November have follicles expanded with a dense, highly refractive, acidophilic material. The epithelium is somewhat flattened and the acini enlarged and more angular than those of the fry (fig. 19). In the glands of the latter (4 to 6 cm. fish) the follicles are smaller, ranging from 0.05 to 0.2 mm. in diameter, more uniform in size and quite spherical (fig. 11). The same seasonal variations presumably occur in the thyroids of the large sea salmon. Because of the larger size of these glands and the fact that certain portions may show signs of activity while other parts are relatively passive, the process cannot be followed so readily in the largest fish. From these findings and those of von Hagen (1936) and Lieber (1936) it may be concluded that thyroid changes are associated with the seasonal activities of teleosts.

Metamorphosis

Before entering upon its life in the sea the young salmon undergoes a characteristic transformation. Superficially the plump well fattened little parr becomes thin and slender. A silvery layer of guanin covers the prominent parr markings. The young fish assumes the appearance of a miniature adult salmon. Gross dissections reveal the fact that the visceral fat deposits, so prominent in the parr,

have been lost. Scale examinations show that although new circuli are being added they are intermediate in character between the narrow bands of the parr and the very wide bands which are formed in the sea. These circuli are quite typical of this transitional period or so-called smolt stage, whether they are formed in the upper reaches of the river or under estuarial conditions. Experiments, performed by Dr. A. G. Huntsman and myself, have demonstrated a complete inability of parr of all sizes to become adapted to salt water. The smolt, on the contrary, can pass directly from the river into the sea (Hoar, 1937; Huntsman and Hoar, 1937). Lovern (1934) has shown that the animal is undergoing changes in its biochemical constitution. In studies of fat metabolism he found a transition from the typical fats of fresh water fish to those of the sea salmon during the smolt stage. He states that "when the parr becomes a smolt it becomes indistinguishable from an adult salmon except in point of size;" and concludes that the "whole metabolism undergoes a change at this period". The smolt transformation is accompanied by a precipitous fall in the coefficient of condition of the fish (Hoar, 1939). The changes taking place in the young salmon at this time seem to be of such a fundamental nature that the smolt stage may be termed a "metamorphosis". In view of the oft-demonstrated relationship between metamorphosis and the thyroid gland in other forms, the salmon material has been examined for comparison.

The Margaree smolt leave the river during the last two weeks of May and the first two weeks of June. The peak of the run occurs during the first spring tides of June (Elson, 1937). Material was collected at all points on the river system and during the entire period of migration.

Smolt metamorphosis is correlated with a pronounced increase in the activity of the thyroid gland (figs. 19 and 20). As evidence of this there is always an increase in the height of the cells from cuboidal to columnar or high columnar, together with an increase in the number of cells and in the number and size of the follicles. This results in an actual increase in the size of the gland (figs. 12 and 13). Moreover the colloid decreases in amount and in the intensity of its staining reaction. In the very active glands the proliferation of the epithelium results in the infolding and tufting of the follicles. The colloid is entirely withdrawn from these extremely active follicles and a strongly basophilic colloidal material is evident in the lymphatics (fig. 18). Numerous small follicles are apparently budded off from the walls of the larger ones. In the less hyperplastic glands there is simply an increase inthe height and number of cells and in the size and number of the follicles. Tufting is not always evident and considerable colloid may be found in the acini. This colloid is, however, always less acidophilic than that of the parr and contains numerous chromophobic peripheral vacuoles. All intermediate degrees of

activity are found. In general the more hyperplastic glands occur in smolts which undergo metamorphosis earliest in the season. After the first week of June involution of the gland commences. Colloid collects in the follicles, the epithelium again becomes cuboidal and the gland assumes as nearly as possible the picture described for the young parr in the summer.

The process of involution cannot be followed in detail. Samples of salmon taken during their first summer in the sea are rare. However the thyroid of the mature salmon shows the results of this change. Adult salmon thyroids consist of large macroscopic acini (1 to 2 mm. in diameter) surrounded by numerous microscopic ones (figs. 16 and 21). Both large and small follicles are completely filled with a dense acidophilic colloid. The vesicles are bounded by a cuboidal or low cuboidal epithelium. The picture is similar to that of the so-called "colloid" goiter. The origin of the large acini is of interest. Baber (1881) has suggested that large follicles may form through the coalescence of the smaller ones. In my material examples of the small acini opening into the larger ones seem to be present (fig. 21). However, it must be remembered that with the increase in epithelium during the smolt stage the actual epithelial surface of the follicle has become very great. In the smolt glands large tufted vesicles with numerous small ones budded off from them are present (fig. 18). The expansion of these by the

collection of colloid would result in the arrangement seen in the adult gland. Fusion of follicles may occur but the hyperplasia of the gland during the smolt transformation probably accounts for most of the large acini.

It is not known how soon involution occurs after the salmon enters the sea. One year sea salmon, (grilse) have thyroids in this condition. Thyroids of smolt forced to remain in the fresh water (land-locked salmon) were collected throughout the summer. From these it appears that the gland, after the pronounced hyperplasia of the smolt stage, undergoes a certain amount of involution but remains fairly active throughout the summer. The picture of extreme involution is attained in the fall. From the studies of sea salmon it appears that the thyroid never again attains the degree of activity which it shows during the first summer after the smolt metamorphosis. The architecture of these adult salmon glands is somewhat different from that of the smaller individuals already described. Due to the great increase in the amount of tissue the gland has become very compact and almost nodular in appearance. Large masses of thyroid acini are separated by connective tissue, and in places the gland has expanded to the point of forcing the neighboring connective tissue into the form of a delicate capsule (fig. 16). In these respects the thyroid of the mature salmon is similar in arrangement to certain species described by Gudernatsch (1911), where the follicles assume a lobular appearance.

This condition is in contrast to that described by Burne (1926) for Lophius. In this form the thyroid tissue is much more compact in the young individuals.

Sexual Maturation

A mild degree of thyroid activity has been associated with sexual activities in a number of the higher vertebrates (Chouke et al, 1935; Elterich, 1936; Krjlow and Sternberg, 1932). Some workers, however, have failed to find any definite relationship (Zalensky, 1935). Kippen and Loeb (1936) find that gonadectomy in the guinea pig causes increased thyroid activity. Such studies have been less numerous among the lower vertebrates. The work of Lieber (1936) seems to have been the only study of this nature on fish material. She found that the sexual maturation of Misgurnus fossilis L. was associated with reduced activity of the thyroid gland.

Again, the salmon parr has been used for the majority of these studies. The male parr are remarkable in that they regularly attain sexual maturation in the fall before going to sea. These little fish, less than one-tenth the size of an adult salmon mature at the end of their second or third year and sometimes at the end of the first. The significance of this has not been explained. An examination of the testes of these fish has shown that the maturation is identical with that occurring in the large sea salmon (figs. 22 and 23). Mr. H. C. White of the Fisheries Research Board of Canada tells me that he has seen these little fish engaging with

large females in spawning, and that he has successfully fertilized eggs with their milt.

A series of thyroids from parr in various stages of maturation has failed to show any definite relation between this gland and the development of the testis. For example, of two male parr collected on August 31, 1938, one was rapidly reaching sexual maturity and the other showed no signs of such a change. Both fish were of about the same size. Their testes are illustrated in figure 22. Their thyroids show no definite difference in activity. Both are in the state of mild activity found at this time of the year. The gland of the immature specimen appears slightly more active, although the difference is no more than might be expected as the result of individual variations. Figure 14 shows photomicrographs of the thyroid of the sexually maturing individual. Again, male and female parr taken on November 16th, when the males were in the act of spawning, gave no more definite results. Figure 23 shows the mature and partially spent testis of the male and the very immature ovary of the female. The thyroids of both are quite inactive as might be expected at this time of the year.

As a check on these results the glands of male and female adult spawning salmon were examined. The results were the same. The thyroids of both are relatively inactive, although in this case that of the female was more active than that of the male.

From these findings it is concluded that sexual maturation of the Atlantic salmon is not correlated with changes in activity of the thyroid.

Discussion

In the Atlantic salmon thyroid activity is associated with the periods of most rapid growth of the bodily tissues, and with fundamental changes in the biochemical constitution of these tissues. The latter part of May and the month of June is the season of rapid growth in the salmon. During this period the fish accumulates the greater part of its fat storage for the whole year (Hoar, 1939). This is also the period of greatest seasonal activity in the thyroid gland, as evidenced by a complete removal of colloidal material from the follicles. Throughout the remainder of the summer, while the fish is still taking food and maintaining this condition, a mild degree of thyroid activity is found. With the approach of winter and the cessation of feeding and active movements the thyroid becomes quite inactive, as shown by the accumulation of a dense acidophilic colloid and a decrease in the height of the epithelium.

Seasonal changes in thyroid activity have been found in both warm and cold blooded animals. These changes, however, occur at different times in the two groups. In general the cold blooded animals show a heightening of activity during the spring and summer. This has been proven true for fishes

(Lieber, 1936), amphibians (Meisenheimer, 1936; Weigmann, 1932; Holzapfel, 1937), and reptiles (Evans and Hegre, 1938). In the warm blooded animals the period of greatest thyroid activity occurs in the winter, and is related to high metabolism in cold weather (Miller, 1939). It is significant that in hibernating mammals, whose metabolism is at a low ebb in the winter, the time of greatest thyroid activity is in the spring (Adler, 1920). In either group of animals thyroid activity, as is to be expected, is associated with the season of greatest metabolic activity. Experiments on mammals have shown that low temperatures stimulate thyroid activity (Ludford and Cramer, 1928; Baillif, 1938). However, since the greatest activity of the thyroid of lower vertebrates occurs in warm weather, it would seem that temperature effects on the thyroid are indirect.

The greatest degree of thyroid activity in the Atlantic salmon is associated with the initiation of the period of most rapid growth and with fundamental biochemical changes in the tissues of the fish. This period, the smolt stage, seems to be a time of complete metamorphosis of the salmon. The intimate relationship of the thyroid gland to metamorphosis of the amphibians has received much attention (Ingram, 1929; Charipper, 1929; Grant, 1931; Etkin, 1936; D'Angelo, 1939). Murr and Sklower (1928), and von Hagen (1936) have established this relationship in connection with the metamorphosis of the eel. Horton (1934) has obtained negative

evidence for the lamprey transformation. However, it would seem that metamorphosis in the fishes and amphibians is usually associated with a marked increase in the activity of the thyroid gland.

Thyroid studies in relation to the sexual cycle are less convincing. Conflicting results obtained by workers on birds and mammals have already been pointed out. Among the lower vertebrates injections of gonadotropic hormones have been found to stimulate the thyroid (Evans and Hegre, 1938; Mellish and Meyer, 1937) while sexual maturation itself is associated with reduced thyroid activity (Lieber, 1936). In the Atlantic salmon no relationship between sexual maturation and thyroid activity is evident. The results may indicate species variations in this respect or that some of the results are complicated by the influence of other factors on the thyroid.

The histophysiological findings tend to clarify some of the results of the early anatomical investigations. It has been stated that the type of thyroid epithelium is different in different species of fishes (Burne, 1926; Gudernatsch, 1911, Maurer, 1886). Marine (1928) states that it is cuboidal in teleosts and columnar in the elasmobranchs. Epithelial height is correlated with the physiological state of the organ and probably varies from time to time in the thyroid of any species. Again, Ferguson (1911) finds that the size of the follicle is proportional to the size of the

fish. This is true in the salmon also, but should be interpreted as signifying a hyperplastic condition at some time in the development of the animal. Gudernatsch (1911) points out that epithelium of the thyroid gland becomes lower and that the colloid becomes more acidophilic with age. This occurs in the salmon and has been found in a number of different animals (Abbott and Prendergast, 1934). It should be taken as evidence of the fact that the thyroid is more active during the early part of life.

ABSTRACT

The anlage of the thyroid gland of the Atlantic salmon, Salmo salar L., appears during the eleventh week of incubation when the embryo is approximately 8.5 mm. long. The pharyngeal region is partially differentiated at this time. Five gill arches are mapped out as lateral concentrations of mesoderm, the epithelial pouches and grooves, with the exception of the first true gill cleft, being solid between. There is no indication of cartilage formation, nor have the copulae of the arches appeared ventral to the solid pharynx. Two blood vessels, the hyoids, extend cranially from the S-shaped tubular heart into the hyoid arch, but the aortic arches proper are as yet undeveloped.

The thyroid anlage arises as a solid knob-like proliferation from the entoderm of the mid-ventral floor of the pharynx at the caudal margin of the hyomandibular junction. The nuclei of the cells soon become arranged around the

periphery of the mass, leaving a clear cytoplasmic area within. No evidence of a lumen, however, is seen at any time. The anlage increases in size and its unattached extremity comes to lie in the bifurcation of the truncus arteriosus.

The development of the basihyoid cartilage and the rapid cranial growth of the lower jaw during the thirteenth and fourteenth week (9 mm. embryos) tend to sever the anlage from the floor of the pharynx. Since the thyroid, heart and associated vessels do not grow forward with the jaw their position becomes relatively more caudal. The result of this positional change is that, by the end of the seventeenth week, the thyroid although still in the bifurcation of the ventral aorta is entirely caudal to the basihyoid complex. At this time the cranial portion of the anlage lies dorsal and rostral to the bifurcation, while the caudal and lateral portions lie beneath the border of the hyoid vessels at their point of origin.

When the embryo is between 10 and 11 mm. long the cells of the thyroid anlage become arranged into solid spherules in which colloidal material collects and the structure shows evidence of breaking up and scattering. At this same time the ventral aorta is developing into an elongated vessel from a sac-like expansion of the cranial end of the heart. The actively proliferating thyroid tissue simply spreads out around this elongating vessel in whatever space is available. There is no evidence of an active migration of the follicles.

The process of primary follicle formation is seen to involve a proliferation of cells, the rearrangement of these into solid spherules, cavity formation within the spherules and the collection of chromophobic and finally chromophilic material within the cavities. Secondary follicles arise from the primary follicles through a process of budding.

By the time the embryo is 11 mm. long three more or less distinct, but not entirely separate masses, of thyroid tissue are evident. These consist of areas of undifferentiated thyroid tissue together with primary follicles containing typical colloid. Two of these masses lie dorsal and one lies ventral to the aorta. The anterior dorsal mass is found at the cranial border of the ventral aorta and the posterior dorsal mass at the level of the second aortic arch. The differentiating thyroid tissue seems to have been forced into these positions by the growth of surrounding structures. The same general arrangement of the thyroid is evident in the reconstructions of the glands of salmon of all ages. Although the proliferation of thyroid tissue continues during the entire period of growth the gland has attained its final form by the time the fish is 28 mm. long. The bulk of the organ increases but the same general boundaries are always maintained after this time.

The thyroid of the adult salmon is a diffuse organ consisting of independent follicles scattered in the loose connective tissue of the throat region. Only in the very

large salmon do the acini become so closely related as to form a compact and nodular gland. The thyroid tissue extends from the caudal border of the first basibranchial to a short distance behind the common origin of the third and fourth aortic arches. It is not normally found cranial to the hyoid complex, but in a few cases anomalies occur in the region of the primary anlage, i. e. the hyomandibular junction. The largest mass of the adult gland is found around the second aortic arches. There is little thyroid tissue lateral to the ventral aorta, and the number of follicles ventral to this blood vessel is always less than the number dorsal to it.

The characteristics of the thyroid acini do not differ from those of other vertebrates. In salmon the follicles are supported by a fatty connective tissue of a reticular nature. The adipose cells have a peculiar vacuolated appearance when treated with osmic acid. Elastic fibers and smooth muscle cells identified by some investigators could not be found.

Lymphatics seem to play a predominant role in the vascularization of the salmon thyroid. Although the hypobranchial artery was studied, branches from this to the thyroid tissue could not be found, nor could the thyroid veins be identified. On the other hand a complicated system of lymphatics formsa large sinus about the thyroid tissue. This sinus consists of a large dorsal channel and a smaller ventral vessel with many lateral connections between the two. The system communicates with the inferior jugular veins in

the cranial direction and drains into the pericardial lymph sinuses caudally. Intimate contact is formed between the epithelium of the follicles and the endothelium of the lymphatics. In the more massive glands lymph capillaries extend from the main sinus between the acini. Although it cannot be said that blood capillaries are unimportant in the physiology of the salmon thyroid, it seems evident that the lymphatics play an important role in the removal of the colloid.

Histophysiological studies have shown a correlation between the functional condition of the thyroid gland and the activities of the Atlantic salmon. Seasonal changes in thyroid activity are very definite. Like all cold blooded animals the salmon shows an increase in thyroid activity during the spring and summer, with a marked decline in the fall and winter. As evidence of this there is a complete withdrawal of colloidal material from the follicles during the early part of June. This coincides with the period of most rapid growth of the fish. Throughout the summer a lightly acidophilic colloid with numerous chromophobic peripheral vacuoles indicates a mild degree of activity. Dense acidophilic colloid within the follicles during the fall and winter is characteristic of a passive gland. However, seasonal activity of the salmon thyroid is not great enough to cause a pronounced increase in the height of the epithelium or inthe size of the follicle. In general it is found that the glands of the young salmon are more active

than those of the older fish.

An active hyperplasia of the thyroid occurs during the smolt stage, that is when the young fresh water fish undergoes changes preparatory to its migration to the sea. The changes taking place in the salmon at this time seem to be of sufficient magnitude to warrant the classing of this period as a "metamorphosis" and comparing it with metamorphosis as seen in other forms. Different degrees of thyroid activity are found in the smolt, but the follicles always show a change in the epithelium from cuboidal to columnar, together with an increase in the size of the follicle and in the number of follicles. The colloidal material becomes much less acidophilic and may be entirely withdrawn from the acini and appear in the neighboring lymphatics. This activity occurs in the early spring and is followed by a partial involution of the gland during the summer of the same year. Involution becomes complete as winter approaches and the thyroid assumes the appearance of a gland of "colloid goiter". In other words the thyroids of the large sea salmon consist of very large macroscopic follicles associated with numerous small microscopic ones. This condition is seen to be the result of the collection of colloid in the hyperplastic follicles of the smolt. The gland has become so enlarged in these adult salmon that it often forces the neighboring connective tissue into the semblance of a capsule.

The male salmon parr is precocious in its sexual development. Significant changes in the structure of the thyroid gland are not found during the process of sexual maturation either in the parr or in the large adult fish.

ACKNOWLEDGMENTS

This work has been made possible through the cooperation of a number of persons. Special thanks are due to Dr. Alice S. Woodman, under whose supervision the study was made. I am also indebted to Dr. D. L. Belding, of Boston University Medical School; Dr. H. I. Battle, of the University of Western Ontario; and members of the Fisheries Research Board of Canada, who supplied or aided in the collection of materials. The drawing of figure 2 was prepared by Mrs. D. Moore.

BIBLIOGRAPHY

ABBOTT, A. C., and J. PRENDERGAST 1934 Histological variations in animal thyroids in western Canada. Can. Med. Assoc. J., vol. 31, pp. 465-473.

ADDISON, W. H. F., and M. N. RICHTER 1932 A note on the thyroid gland of the swordfish (Xiphias gladius L.). Biol. Bull., vol. 63, pp. 472-476.

ADLER, L. 1920 Schilddrüse und Wärmeregulation (Untersuchungen an Winterschläfern). Arch. Exper. Path., Bd. 86, S. 159-224.

ALLEN, W. F. 1906 Distribution of the lymphatics in the head of Scorpoenichthys marmoratus. Proc. Wash. Acad. Sci., vol. 8, pp. 41-90.

ANDERSON, O. A. 1894 Zur Kenntnis der Morphologie der Schilddrüse. Arch. f. Anat. u. Phys. Anat. Abt. pp. 177-224.

BABER, S. C. 1881 Researches on the minute structure of the thyroid gland. Phil. Trans. R. Soc. London, vol. 172, pp. 577-608.

BELDING, D. L., M. J. PENDER, and J. A. RODD 1932 The early growth of salmon parr in Canadian waters. Trans. Am. Fish. Soc., vol. 62, pp. 211-223.

BADERTSCHER, J. A. 1918 The fate of the ultimobranchial body in the pig (Sus scrofa). Am. J. Anat., vol. 23, pp. 89-131.

BAILLIF, R. N. 1937 Cytological changes in the rat thyroid following exposure to heat and col, and the relationship to the physiology of secretion. Am. Journ. Anat., vol. 61, pp. 1-19.

BRADWAY, W. 1929 The morphogenesis of the thyroid follicles of the chick. Anat. Rec., vol. 42, pp. 157-167.

BURNE, R. H. 1926 A contribution to the anatomy of the ductless glands and lymphatic system of the angler fish (Lophius piscatorius). Phil. Trans. Roy. Soc. London, s.B., vol. 215, pp. 1-56.

CHARIPPER, H. A. 1929 Studies on amphibian endocrines. I. The thyroid gland of Necturus maculosus. Anat. Rec., vol. 44, pp. 117-141.

CHOUKE, K. S., H. FRIEDMAN and L. LOEB 1935 Proliferative activity of the thyroid gland of the female guinea pig during the sexual cycle. Anat. Rec., vol. 63, pp. 131-137.

COOPER, E. 1925 Human Endocrine Glands. Oxford Med. Publ.

COWDRY, E. V. 1921 Flaggelated thyroid cells of the dogfish (Mustelus canis). Anat. Rec., vol. 22, pp. 289-299.

..... 1934 A Textbook of Histology. 1st edition. Lea and Febiger, Philadelphia.

D'ANGELO, S. A., and H. A. CHARIPPER 1939 The morphology of the thyroid gland in the metamorphosing Rana pipiens. J. Morph., vol. 64.

ELTERICH, C. F. 1936 Uber zyklische Veränderungen der Schilddrüse in den einzelnen Geschlechtsphasen der Taube. Endokrinologie, Bd. 18, S. 31-37.

EMBODY, G. C. 1934 Relation of temperature to the incubation periods of eggs of four species of trout. Trans. Am. Fish. Soc., vol. 64, pp. 281-289.

ETKIN, W. 1936 The phenomena of anuran metamorphosis. III The development of the thyroid gland. J. Morph. vol. 59, pp. 69-89.

ELSON, P. F. 1937 The smolt run at Margaree Harbour. M. S. Reports, Fish. Res. Bd. Can., 1937.

EVANS, L. T., and E. HEGRE 1938 The effects of ovarian hormones and seasons on Anolis carolinensis. I. The thyroid. Anat. Rec., vol. 72, pp. 1-6.

FERGUSON, J. S. 1911 The anatomy of the thyroid gland of elasmobranchs, with remarks on the hypbranchial circulation in these fishes. Am. Journ. Anat., vol. 11, pp. 151-209.

FLORENTIN, P. 1932 Quelques particularités de l'histogénèse de la glande thyroide chez les Téléostéens. Compt. Rend. Soc. Biol. Paris, T. 109, pp. 467-469.

..... 1927 La vascularisation du corps thyroïde des poissons. Compt. Rend. Soc. Biol. Paris, T. 96, pp. 1157-1159.

FRIEDGOOD, H. B., and W. B. CANNON 1936 Studies on the sympathetic nervous control of the anterior hypophysis. Am. Jour. Physiol., vol. 116, p. 54.

GRANT, M. P. 1931 The mechanism of colloid release from the urodele thyroid during diagnostic stages of metamorphosis (Amblystoma jeffersonianum, Amblystoma opacum). Anat. Rec., vol. 51, pp. 17-41.

GREIL, Herr 1906 Uber die Entstehung der Kiemendarmderivate von Ceratodus F. Anat. Anz., Bd. 29, Verh. Anat. Ges., Bd. 20, S. 115-131.

GUDERNATSCH, J. F. 1911 The thyroid gland of the teleosts. J. Morph., vol. 21, pp. 709-782.

HAGEN, F. v. 1936 Die wichtigsten Endokrinen des Flussaals. Thyroidea, Thymus, und Hypophyse im Lebensyklus des Flussaals (Anguilla vulgaris) nebst einigen Untersuchungen uber das chromophile und chromophobe Kolloid der Thyroidea. Zool. Jahrb. Abt. Anat. u. Ont., Bd. 61, S. 467-538.

HEWER, E. E. 1927 The activity of the thyroid gland in relation to the staining reactions of the colloid. J. Path. and Bact., vol. 30, pp. 621-625.

HILL, B. H. 1935 The early development of the thyroid gland in Amia calva. J. Morph., vol. 57, pp. 533-545.

HOAR, W. S. 1937 The development of the swim bladder of the Atlantic salmon. J. Morph., vol. 61, pp. 309-319.

HOAR, W. S. 1937 Fatness or condition of salmon. M. S. Reports, Fish. Res. Bd. Can., 1937.

..... 1939 The weight-length relationship of the Atlantic salmon. In press, J. Fish. Res. Bd. Can.

HOGBEN, L., and F. A. E. CREW 1923 Studies on the internal secretions. II. Endocrine activity in foetal and embryonal life. Brit. Jour. Exp. Biol., vol. 1, pp. 1-13.

HOLZAPFEL, R. A. 1937 The cyclic character of hibernation in frogs. Quart. Rev. Biol., vol. 12,pp. 65-84.

HORTON, F. M. 1934 On the relation of the thyroid to metamorphosis in the lamprey. Jour. Exp. Biol., vol. 11, pp. 257-261.

HUNTSMAN, A. G., and W. S. HOAR 1937 Resistance of young salmon to sea water. M. S. Reports, Fish. Res. Bd. Can., 1937.

INGRAM, W. R. 1929 Studies of amphibian neoteny. II. The interrelation of thyroid and pituitary in the metamorphosis of neotenic anurans. Jour. Exp. Zool., vol. 53, pp. 387-410.

JACKSON, J. L. 1931 The shape and size of the human thyroid follicle in health and disease. Anat. Rec., vol. 48, pp. 219-239.

KINGSBURY, B. F. 1935 On the fate of the ultimobranchial body within the human thyroid gland. Anat. Rec., vol. 61, pp. 155-173.

KIPPEN, A. A., and L. LOEB 1936 The effect of gonadectomy on the thyroid gland in the guniea pig. Endocrinology, vol. 20, pp. 201-209.

LIEBER, A. 1936 Der Jahreszyklus der Schilddrüse von Misgurnus fossilis L. und seine experimentelle Beeinflussbarkeit. Zeitschr. Wiss. Zool. Abt. A., Bd. 148, S. 364-400.

KRJLOW, L. N., and A. J. STERNBERG 1932 Die Schilddrüsenkolloidveränderung bei Kaninchen unter dem Einflusse des Koitus und der Schwangerschaft. Endokrinologie, Bd. 10, S. 37-43.

KUSCHINSKY, G. 1935 Uber den Einfluss verschiedener Temperaturen auf die Sekretion des thyreotropen Hormons. Arch. Exp. Path. u. Pharmakol., Bd. 179, S. 726-737.

LUDFORD, R. J., and W. CRAMER 1928 The mechanism of secretion in the thyroid gland. Proc. Roy. Soc. London, s.B., vol. 104, pp. 28-39.

MACKENZIE, D. 1915 The histology of the thyroid in animals fed on various diets. Jour. Path. and Bact., vol. 19, pp. 341-348.

MALLORY, F. B. 1938 Pathological technique. W. B. Saunders Co., Philadelphia.

MARINE, D., and C. H. LENHART 1911 Further observations and experiments on the so-called thyroid carcinoma of brook trout (Salvelinus fontinalis) and its relation to

endemic goiter. Jour. Exper. Med.,vol. 13, pp. 455-475.

MARINE, D. 1913 The evolution of the thyroid gland. Johns Hop. Hosp. Bull., vol. 24, pp. 135-141.

..... 1914 Further observations and experiments on goiter (so-called thyroid carcinoma) in brook trout (Salvelinus fontinalis). III. Its prevention and cure. Jour. Exp. Med., vol. 19, pp. 70-88.

..... 1914 The rapidity of the involution of active thyroid hyperplaias of brook trout following the use of fresh sea fish as a food. Jour. Exp. Med., vol. 19, pp. 376-382.

..... 1928 The thyroid, parathyroids, and thymus. Section XVII Special Cytology. Vol. 1, E. V. Cowdry, Paul B. Hoeber, New York.

..... 1935 The pathogenesis and prevention of simple or endemic goiter. J. A. M. A., vol. 104, pp. 2334-2341.

MAURER, F. 1886 Schilddrüse und Thymus der Teleostier. Morph. Jahrb., Bd. 11, S. 127-175.

..... 1888 Schilddrüse, Thymus und Kiemenreste der Amphibien. Morph. Jahrb., Bd. 13, S. 296-382.

MAXIMOW, A. A., and W. BLOOM 1938 A Textbook of Histology. 3rd edition. W. B. Saunders Co., Philadelphia.

MEANS, J. M. 1937 The Thyroid and its Diseases. J. B. Lippincott, Philadelphia.

MERRIMAN, D. 1935 The effect of temperature on the development of the eggs and larvae of the cut-throat trout (Salmo clarkii clarkii Richardson). Jour. Exp. Biol., vol. 12, pp. 297-305.

MCCLURE, C. F. W. 1915 The development of the lymphatic system in fishes with especial reference to its development in the trout. Mem. Wistar Inst. Anat. Biol., No. 4.

MCKENZIE, T. 1884 The blood vascular system, ductless glands and urogenital system of Amiurus catus. Proc. Canad. Inst., Toronto, 3rd Ser., vol. 2, pp. 418-443.

MEISENHEIMER, M. 1936 Die jahrescyclischen Veränderungen der Schilddrüse von Rana temporaria L. und ihre Beziehungen zur Häutung. Zeitschr. wiss. Zool., Bd. 148, S. 261-297.

MELLISH, C. H., and R. K. MEYER 1937 The effects of various gonadotropic substances and thyroxine on the ovaries of horned lizards (Phrynosoma cornutum). Anat. Rec., vol. 69, pp. 179-189.

MILLER, D. S. 1939 A study of the physiology of the sparrow thyroid. J. Exp. Zool., vol. 80.

MINOT, C. S. 1903 A Laboratory Text-book of Embryology. P. Blackiston's Son & Co., Philadelphia.

MULLER, W. 1871 Uber die Entwicklung der Schilddrüse. Jena. Zeitschr. f. Med. u. Naturwiss., Bd. 6, S. 428-453.

MURR, E., and A. SKLOWER 1928 Untersuchungen über die inkretorischen Organe der Fische. I. Das Verhalten der Schilddrüse in der Metamorphose des Aales. Zeitschr Vergleich. Physiol., Bd. 7, S. 279-288.

NORRIS, E. H. 1916 The morphogenesis of the follicles in the human thyroid gland. Am. Jour. Anat., vol. 20, pp. 411-448.

..... 1918a The early morphogenesis of the human thyroid. Am. Jour. Anat., vol. 24, pp. 443-465.

..... 1918b The morphogenesis of the thyroid gland in Squalus acanthias. J. Morph., vol. 31, pp. 187-219.

..... 1937 The parathyroid glands and the lateral thyroid in man. Contrib. Embryol. Carnegie Inst., vol. 26, No. 159, pp. 249-294.

PLATT, J. B. 1896 Development of thyroid and supraperi-cardial bodies in Necturus. Anat. Anz., Bd. 11, S. 557-567.

RAMSAY, A. J. 1938 Comments on the origin and growth pattern of thyroid parenchyma. Anat. Rec., vol. 70, pp. 287-309.

REINHOFF, W. F. 1929 Gross and microscopic structure of the thyroid gland in man. Arch. Surg., vol. 19, pt. 1, pp. 986-1036.

RICE, C. O. 1938 Histological structure of the normal thyroid gland. Arch. Surg., vol. 36, pp. 96-110.

RIDDLE, O. 1927 Studies on thyroids. Endocrinology, vol. 11, pp. 161-172.

ROGERS, W. M. 1927 The fate of the ultimobranchial body in the white rat (Mus norvegicus albinus). Am. J. Anat. vol. 38, pp. 349-375.

SAUNDERS, J. M. 1931 Studies on the thyroid gland of urodeles. Unpublished thesis, Univ. Illinois, quoted from Hill, 1935.

SCHAFFER, J. 1906 Berichtigung die Schilddruse von Myxine betreffend. Anat. Anz., Bd. 28, S. 65-73.

SEVERINGHAUS, A. E. 1933 Cytological observations on secretions in normal and activated thyroids. Zeitschr. Wiss. Biol. Abt., B., Zeitschr f. Zell. u. Mikrosk. Anat., Bd. 19, S. 653-680.

SILVESTER, C. F., 1905 The blood vascular system of the tile-fish, Lopholatilus chamaeleonticeps. Bull. Bur. Fish. Wash., vol. 24, pp. 87-114.

SIMON, J. 1844 On the comparative anatomy of the thyroid gland. Phil. Trans. Roy. Soc. London, vol. 134, pp. 295-303.

STOCKARD, C. R. 1906 The development of the thyroid gland in Bdellostoma stouti. Anat. Anz., Bd. 29, S. 91-99.

UHLENHUTH, E. 1927 Die Morphologie und Physiologie der Salamander Schilddrüse. I. Histologischembryologische Untersuchung der Sekretionprozesses in den verschiedenen Lebenperioden der Schilddrüse der Marmorsalamanders,

Ambystoma opacum. Zeitschr. f. wiss. Biol.Abt. D., Wm. Roux' Archiv. f. Entwick. der Organismen, Bd. 109, S. 612-749.

UHLENHUTH, E. 1937 The thyroactivator hormone; its isolation from the anterior lobe of the bovine pituitary gland and its effects on the thyroid gland. Ann. Int. Med., vol. 10, pp. 1459-1486.

VOGT, C. 1842 Embryologie des Salmones. Histoire Naturelle des Poissons de l'Europe Centrale. L. Agassiz. T. 1.

WATZKA, M. 1933 Vergleichende Untersuchungen über den ultimobranchialen Körper. Zeitschr. f. mikr-anat. Forschung., Bd. 34, S. 485-533.

WEIGMANN, R. 1932 Jahreszyklische Veränderungen im Funktionszustand der Schilddrüse und im Stoffumsatz von Lacerta vivipara Jacq. Zeitschr. wiss. Zool., Bd. 142, S. 492-509.

WILLIAMS, R. G. 1937 Microscopic studies of living thyroid follicles implanted in transparent chambers installed in the rabbit's ear. Am. J. Anat., vol. 62, pp. 1-29.

..... 1939 Observations on the formation of new follicles in living grafts of the thyroid gland in rabbits. Anat. Rec., vol. 73.

WILLIAMSON, G. S., and I. H. PEARSE 1923 The structure of the thyroid organ in man. J. Path. and Bact., vol. 26, pp. 459-469.

WILLIAMSON, G. S. 1926 The applied anatomy and physiology of the thyroid apparatus. Brit. Jour. Surg., vol. 13, pp. 466-496.

WILSON, G. E. 1927 The thyroid follicle in man. Its normal and pathological configuration. Anat. Rec., vol. 37, pp. 31-61.

WILSON, H. V. 1889 The embryology of the sea bass. Bull. U. S. Fish. Comm., vol. 9, pp. 209-278.

WOODMAN, A. S. 1939 Personal communication.

ZALESKY, M. 1935 A study of the seasonal changes in the thyroid gland of the thirteen-lined ground squirrel (Citellus tridecemlineatus), with particular reference to its sexual cycle. Anat. Rec., vol. 62, pp. 109-137.

ZECKWER, I. T. 1932 The effect of cabbage feeding on the morphology of the thyroid of rabbits. Am. Jour. Path., vol. 8, pp. 235-244.

Fig. 1. Graphic reconstructions (x200) of the undifferentiated thyroid anlage (stippled masses) in relation to the hyoid arteries (Hyo) and the bulbous aorticus (BA). a., 12-week Saint John embryo; b., 14-week Saint John embryo. Ventral aspect.

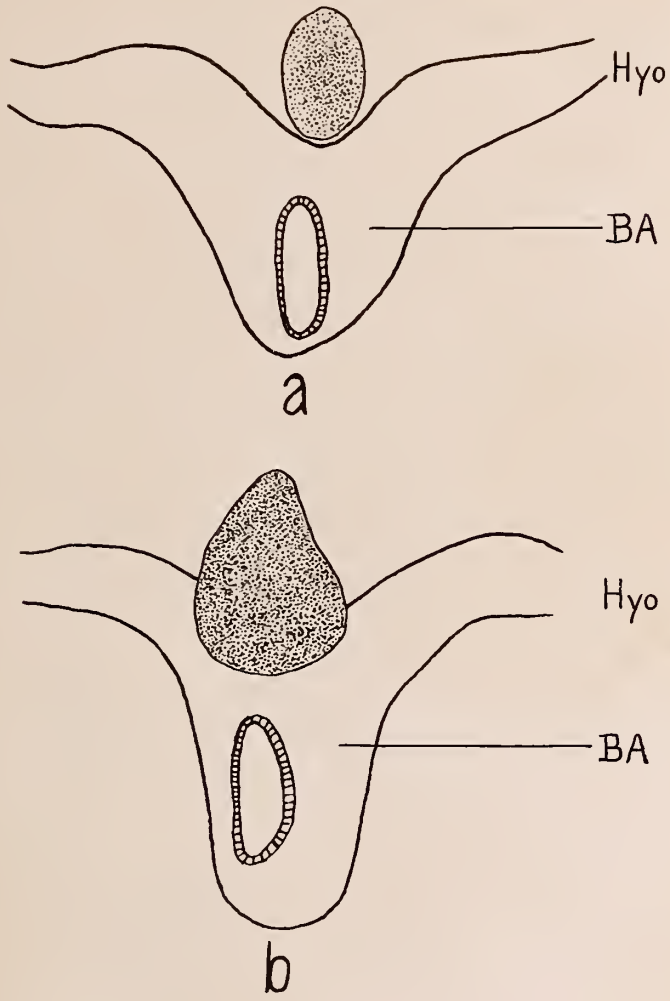

Fig. 1

Fig. 2. Drawing of a wax model (x200) of a portion of one-half of the epithelium of the pharyngeal region in the 12-week Saint John embryo to show the relationship of the thyroid anlage (Th) to the visceral pouches. I, II, III, first three true gill pouches (regions of future gill slits).

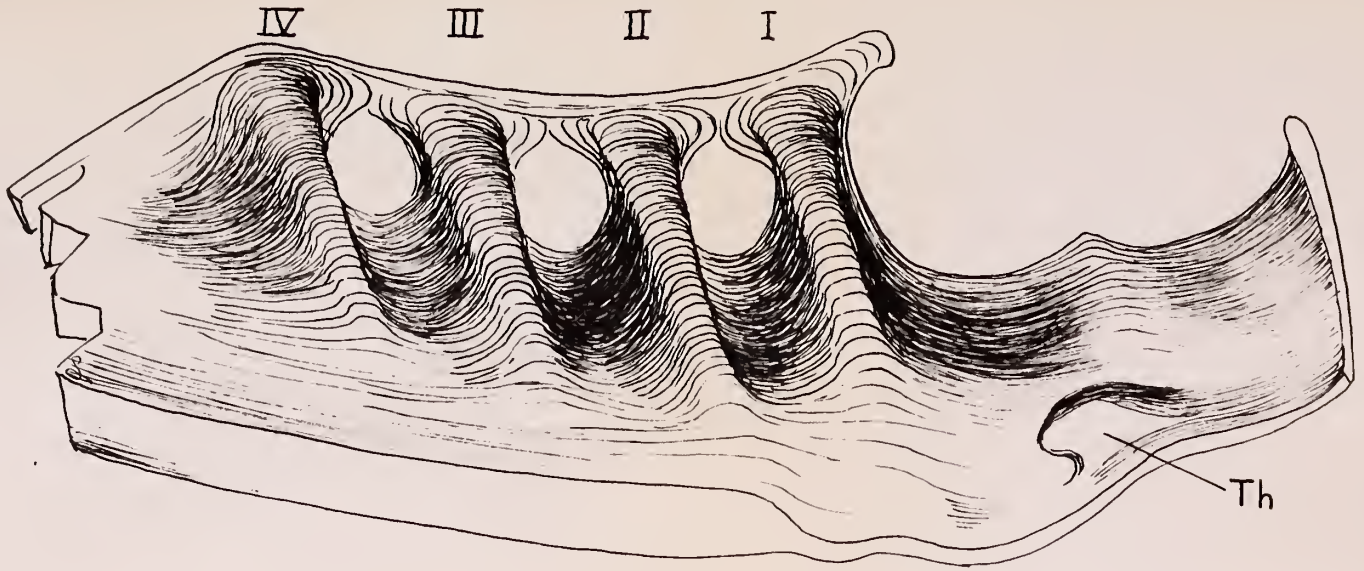

Fig. 2

Fig. 3. Photomicrograph (x200) of a sagittal section of the pharyngeal region of the 11-week Saint John embryo to show the primary thyroid anlage (Th). BA, bulbous aorticus; Ph, solid pharynx; Y, yolk. Haematoxylin and eosin.

Fig. 4. Photomicrograph (x200) of a sagittal section of the pharynx of the 13-week Saint John salmon to show the differentiation of the solid attached anlage (Th). Ph, solid pharynx; BA, bulbous aorticus; BI, blood island. Haematoxylin and eosin.

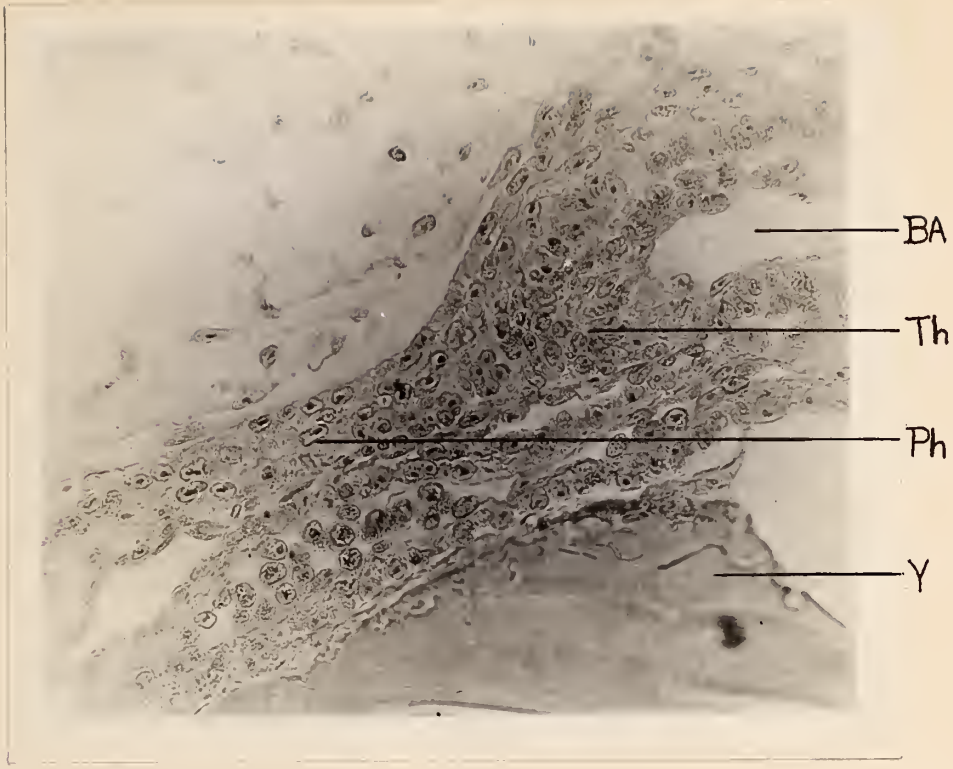

Fig. 3

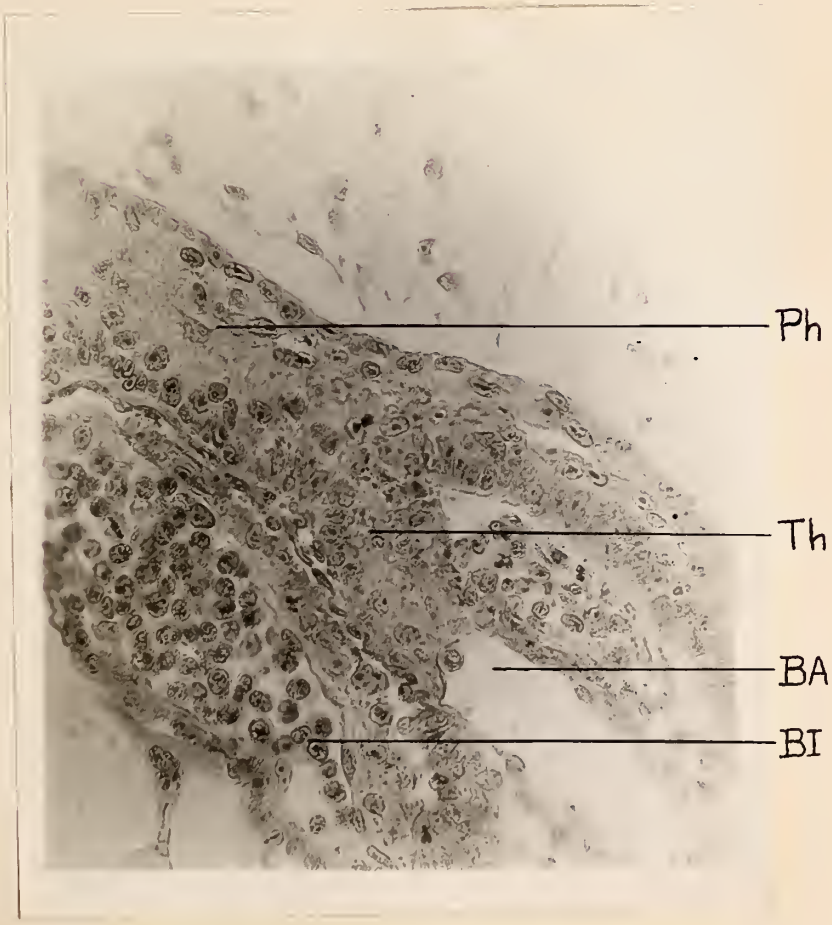

Fig. 4

Fig. 5. Photomicrograph (x90) of a sagittal section of a 14-week Saint John embryo to show the detached and solid anlage (Th) in relation to the basihyoid (BH), the bulbous aorticus (BA), and the mandible (Me). Haematoxylin and eosin.

Fig. 6. Photomicrograph (x40) of a sagittal section of the pharyngeal region of the 51-day Sandwich embryo to show the relatively caudal position of the ventral aorta (VA), and the thyroid (Th). BH, basihyoid; Hyo, hyoid artery; AT, anomalous mass of thyroid; Me, Meckel's cartilage. Haematoxylin and eosin.



Fig. 5

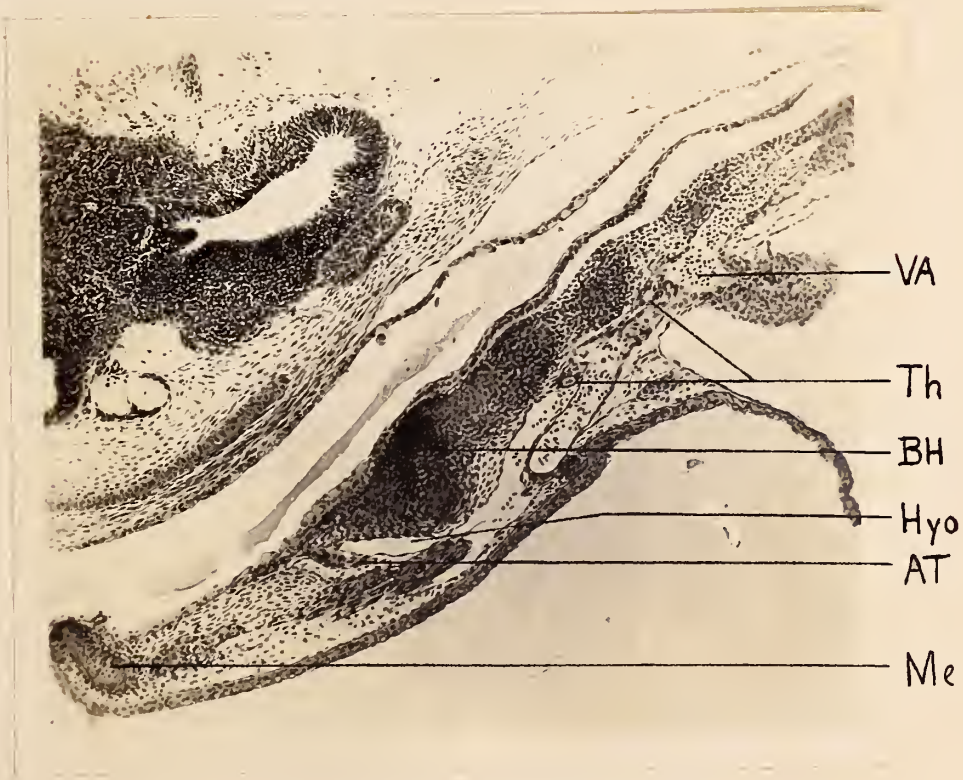

Fig. 6

Fig. 7. Graphic reconstructions (x100) of the thyroid tissue (stippled masses) in relation to the ventral aorta and the aortic arches (I to IV). Hyo, hyoid arteries; BA, bulbous aorticus. a., 44-day; b., 51-day; c., 65-day; and d., 86-day Sandwich fish.

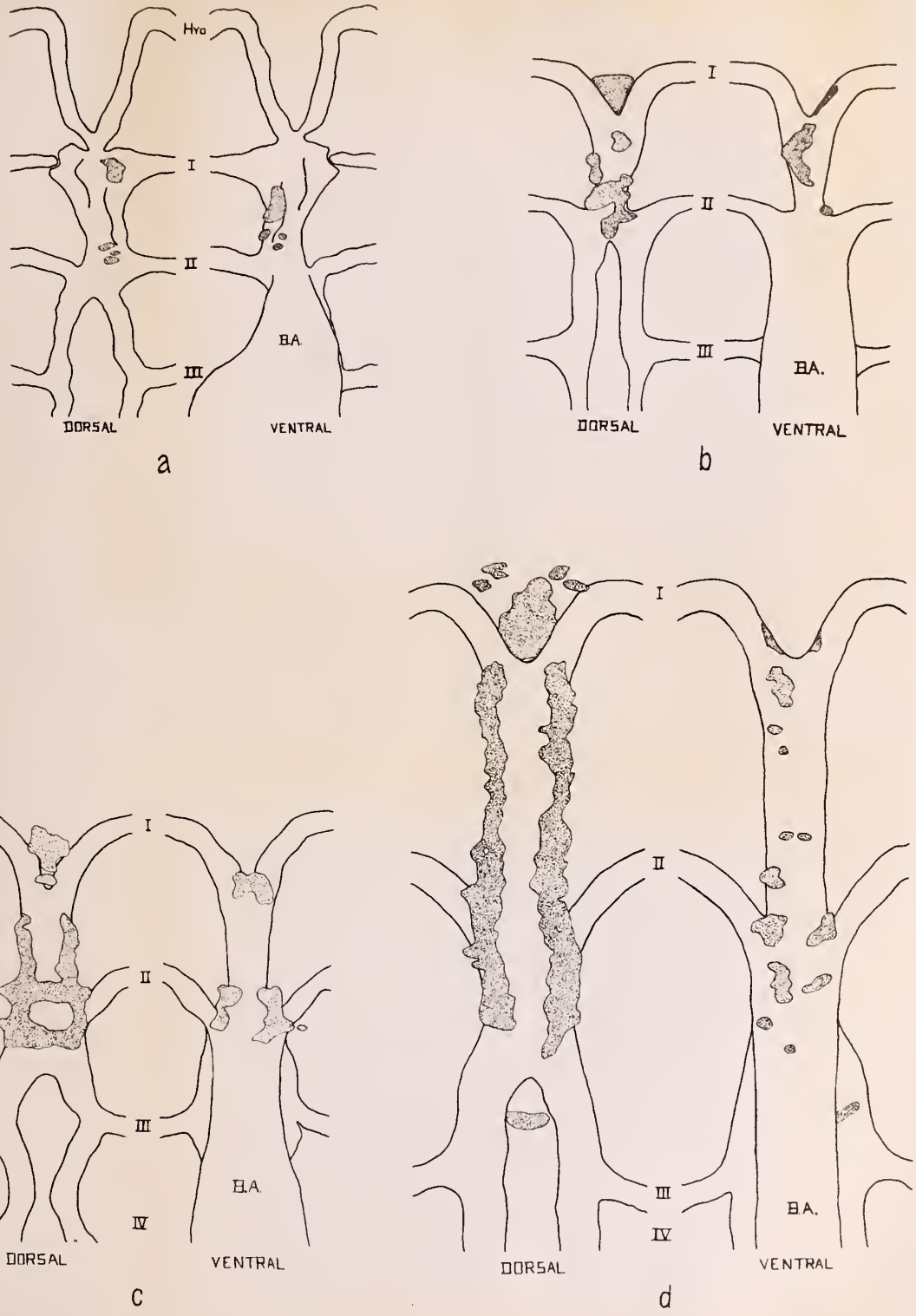
Hyo
I
II
III
BA.
DORSAL
VENTRAL
a
I
II
III
BA.
DORSAL
VENTRAL
b
I
II
III
IV
BA.
DORSAL
VENTRAL
c
I
II
III
IV
BA.
DORSAL
VENTRAL
d

Fig. 7

Figs. 8 and 9. Photomicrographs (x200) of transverse sections of the thyroid regions of the 51-day Sandwich fish to show the differentiation of the primary thyroid follicles (PF) and the lymphatics (L). UT, undifferentiated thyroid tissue; VA, ventral aorta; DF, partially differentiated follicles. Haematoxylin and eosin.



Fig. 8

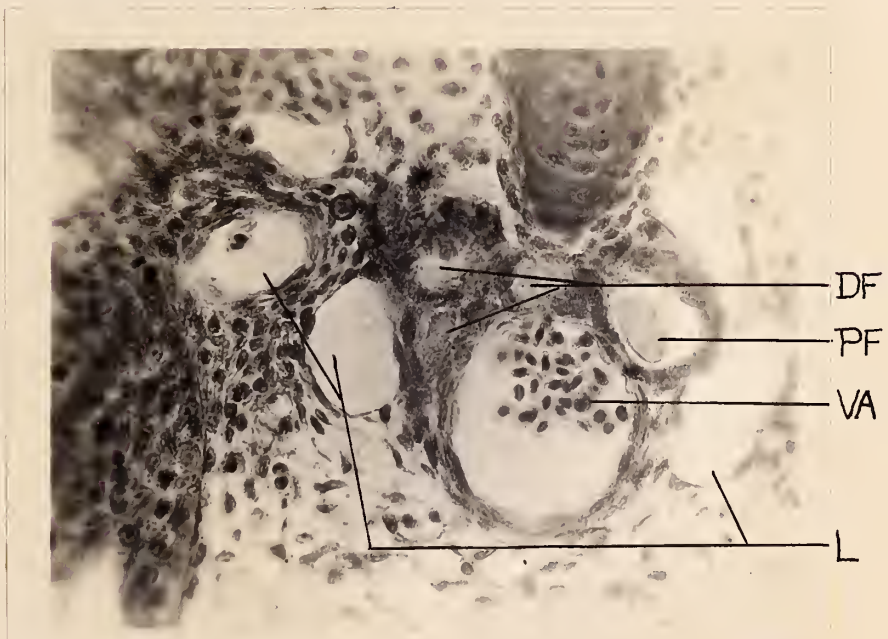

Fig. 9

Fig. 10. Graphic reconstruction (x100) of the thyroid tissue (stippled masses) of the 32-week Saint John fry in relation to the ventral aorta and its branches (I to IV). BA, bulbous aorticus.

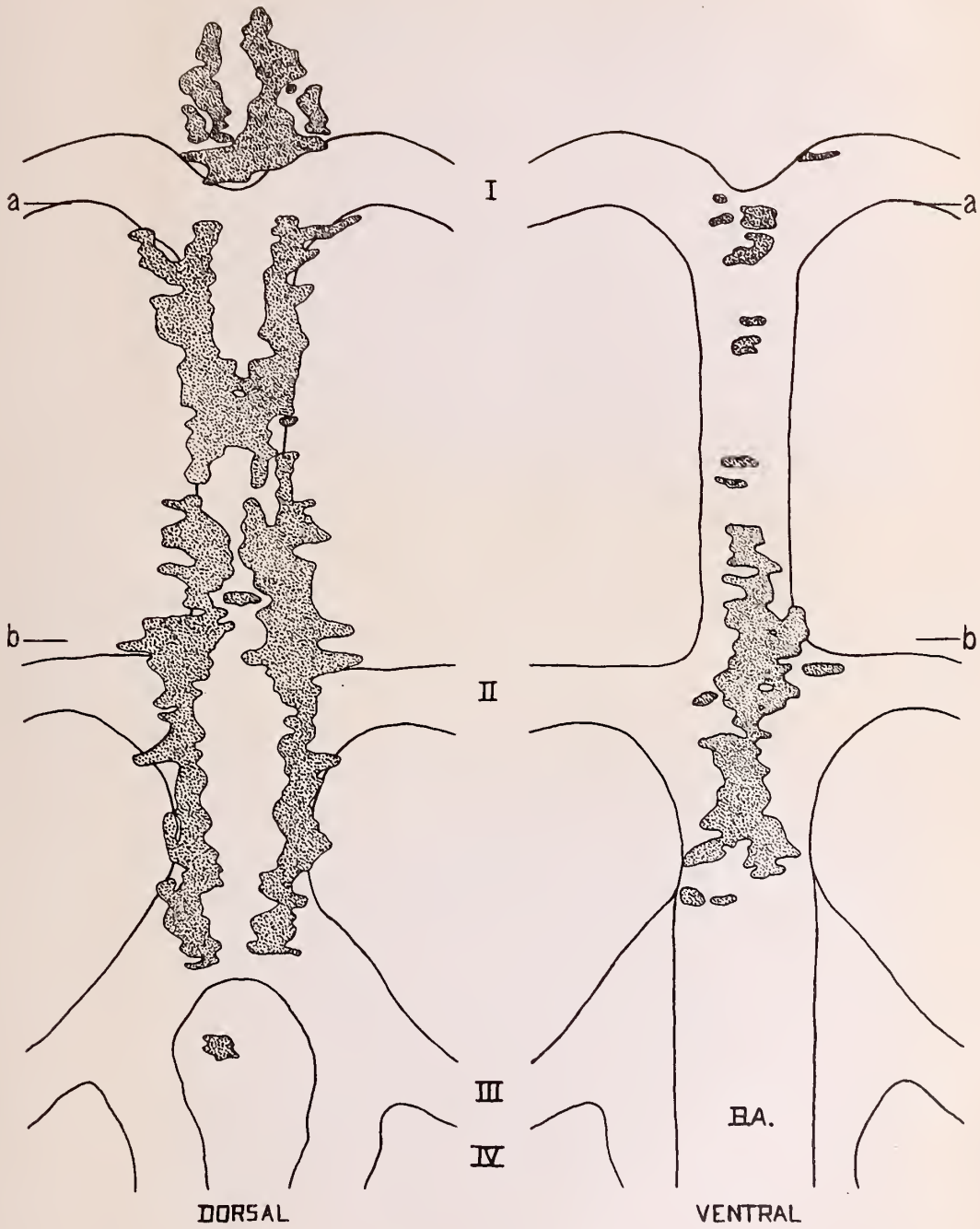

Fig. 10

Fig. 11. Photomicrographs (x80) of transverse sections through the thyroid illustrated in figure 10. a. and b. sections at levels of aa and bb, respectively, of figure 10. HB, hypobranchial cartilage; B, basihyoid; I, first aortic arch; Th, thyroid; L, lymphatic; VA, ventral aorta. Haematoxylin and eosin.

Fig. 11a

Fig. 11b

Fig. 12; Graphic reconstruction (x25) of the thyroid tissue (stippled masses) of a 11.1cm. salmon parr in relation to the ventral aorta and its branches (I to IV). BA, bulbous aorticus.

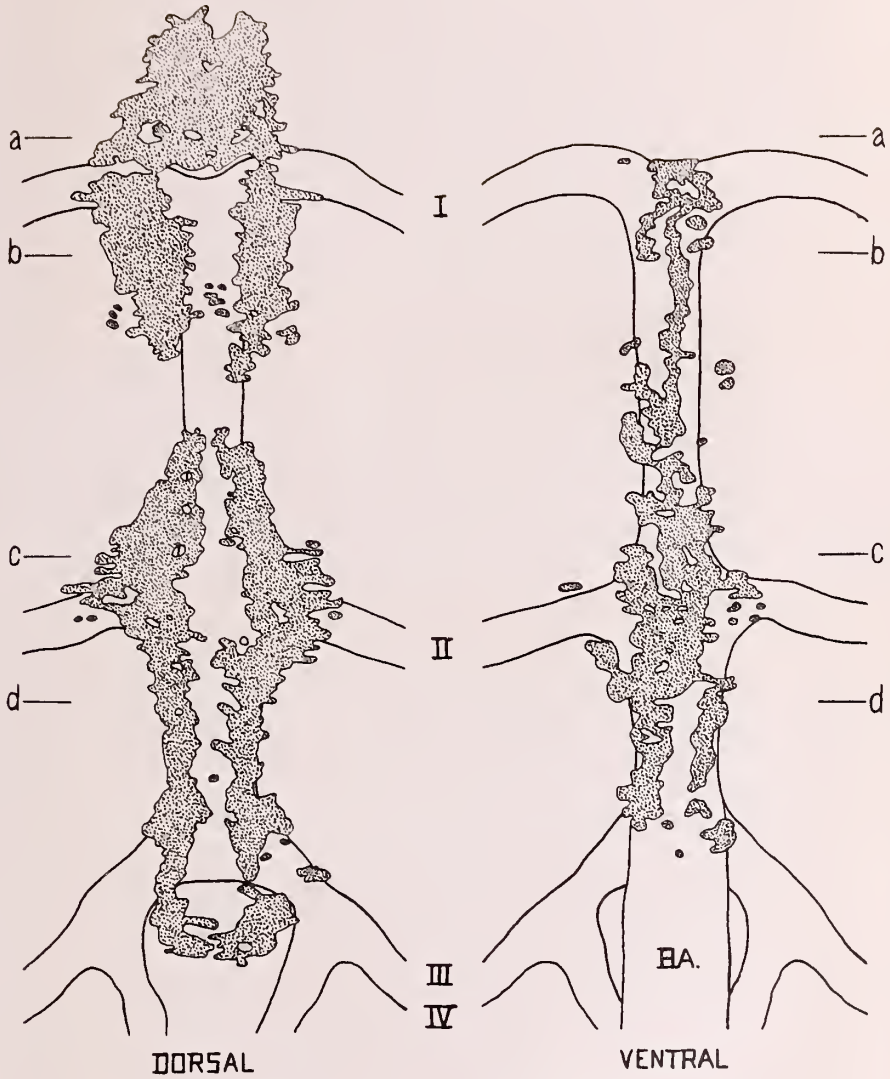

Fig. 12

Fig. 13. Graphic reconstruction (x25) of the thyroid tissue (stippled masses) in a 15.4 cm. salmon smolt in relation to the ventral aorta and its branches (I to IV). BA, bulbous aorticus.

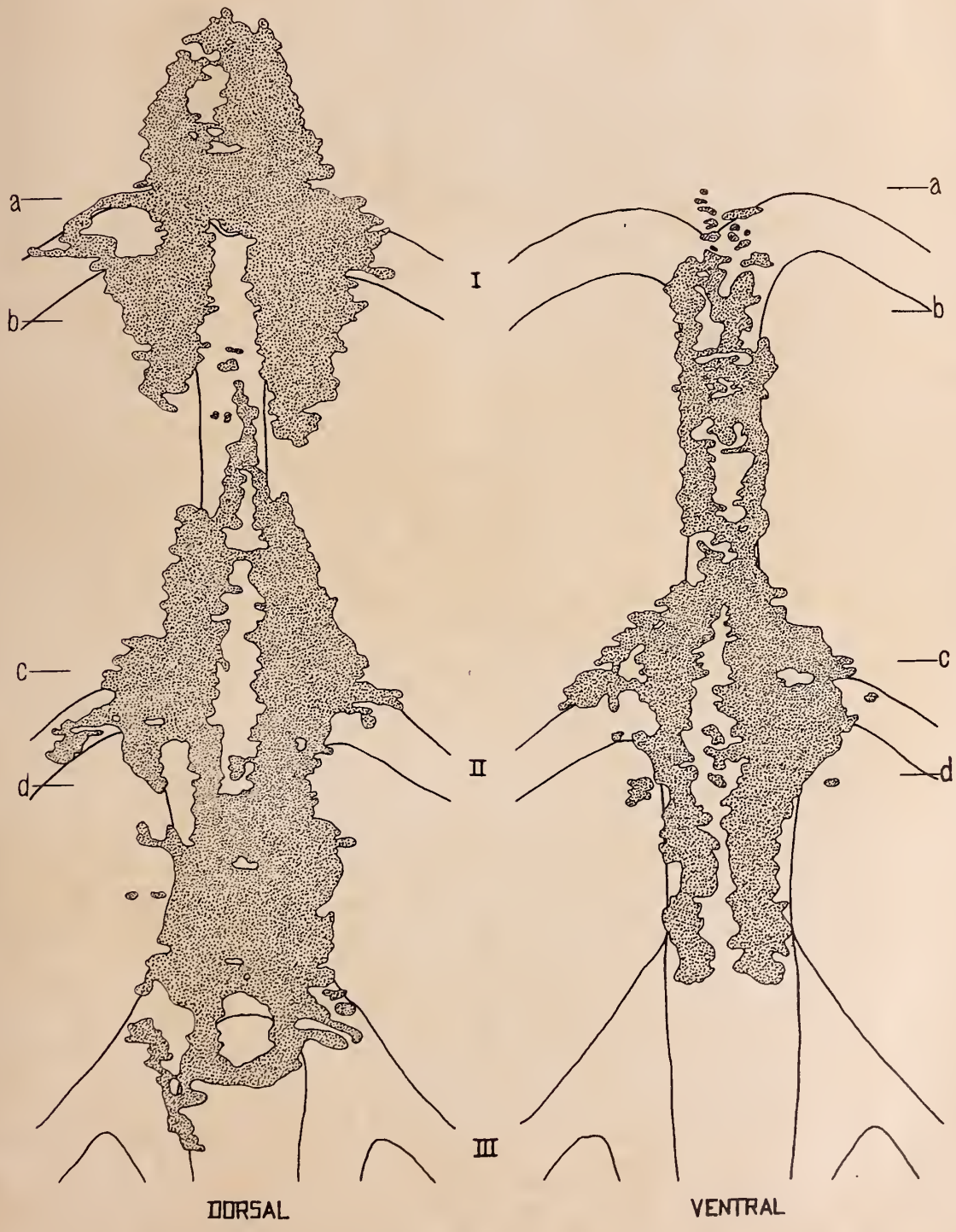

Fig. 13

Fig. 14. Photomicrographs (x40) of transverse sections through the thyroid illustrated in figure 12. CT, fatty connective tissue; B, basibranchial; L, lymphatics; VA, ventral aorta. a, b, c, and d, sections at levels aa, bb, cc, and dd, respectively, of figure 12. Haematoxylin and eosin.

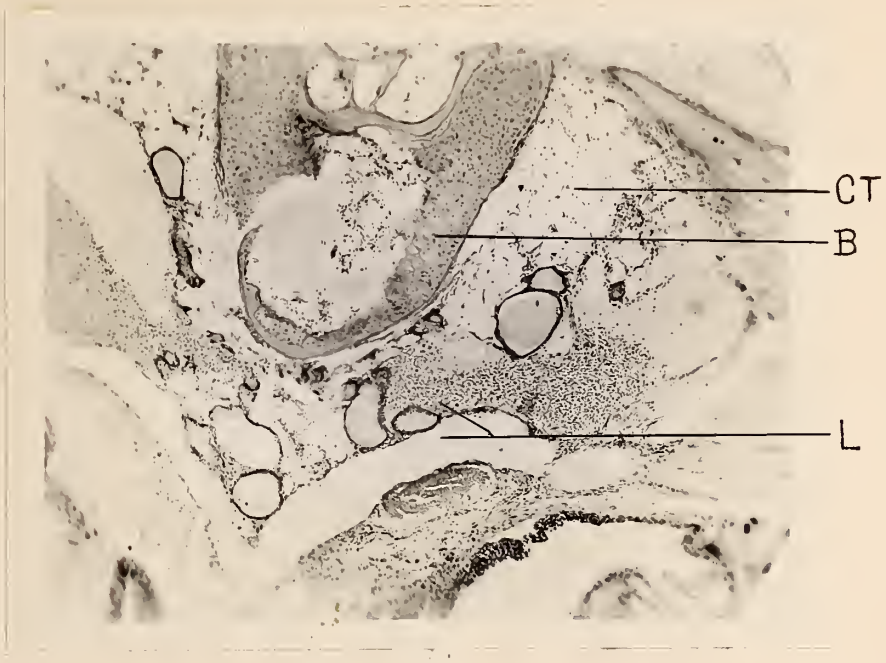

Fig. 14a

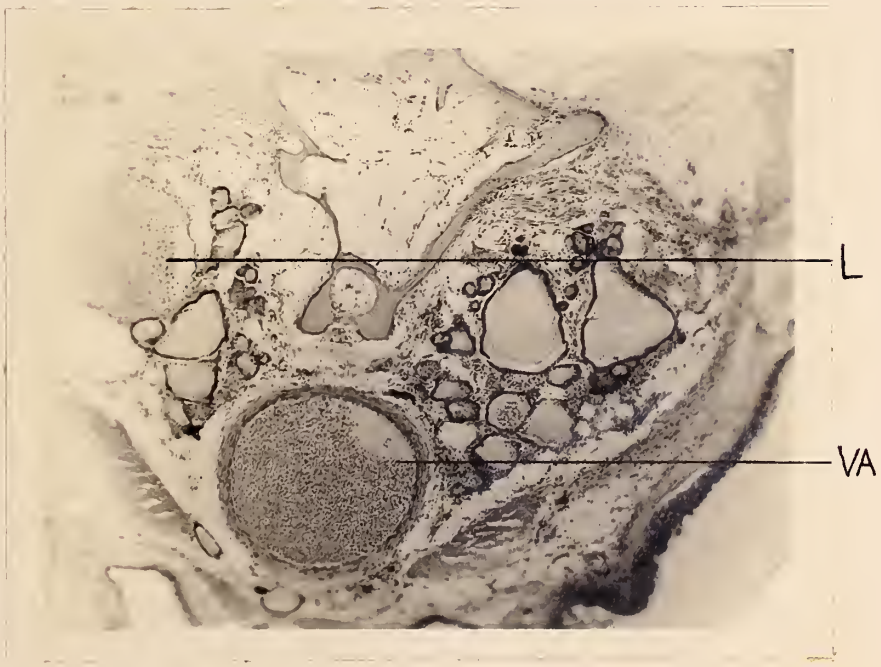

Fig. 14b

Fig. 14 c

Fig. 14 d

Fig. 15. Photomicrographs (x20) of transverse sections of the thyroid and lymphatics illustrated in figures 13 and 17. L, lymphatic; Th, thyroid; C, constricted region of the throat isthmus; Hbr, hypobranchial artery. a, b, c, and d, sections at the levels aa, bb, cc, and dd, respectively, of figures 13 and 17. Haematoxylin and eosin.

Fig. 15a

Fig. 15b

Fig. 15 c

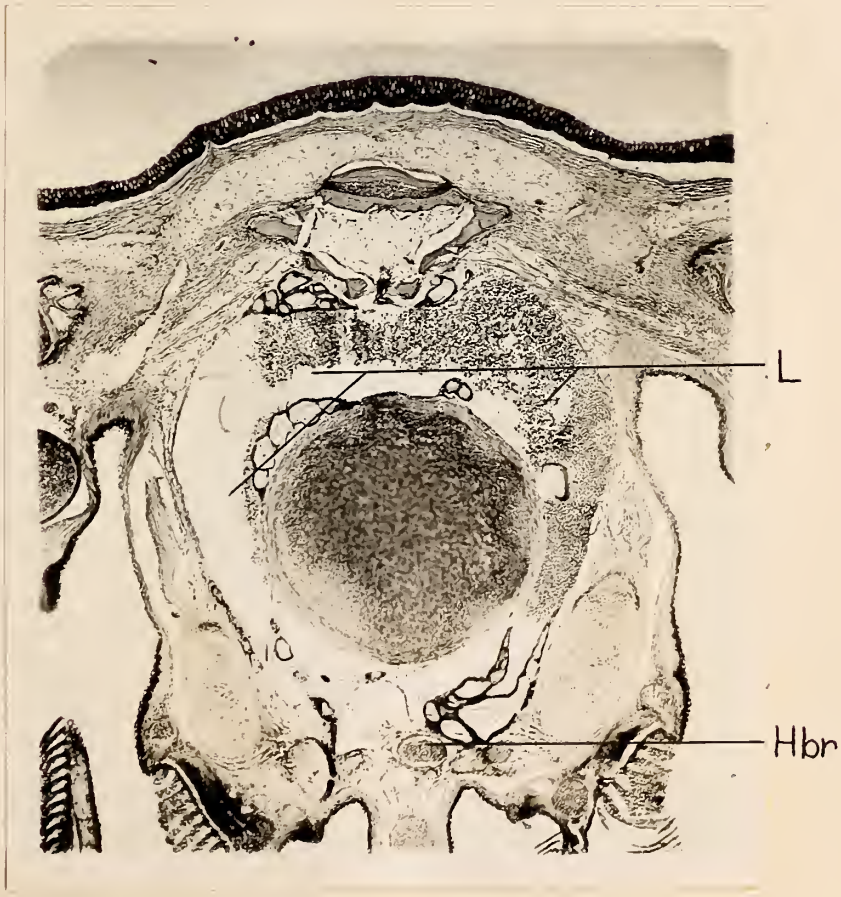

Fig. 15 d

Fig. 16. Photomicrographs (x10) of the thyroid region of an 80 cm. adult salmon. B, basibranchial; L, lymphatic; VA, ventral aorta; III & IV, common origin of aortic arches III and IV. Haematoxylin and eosin.

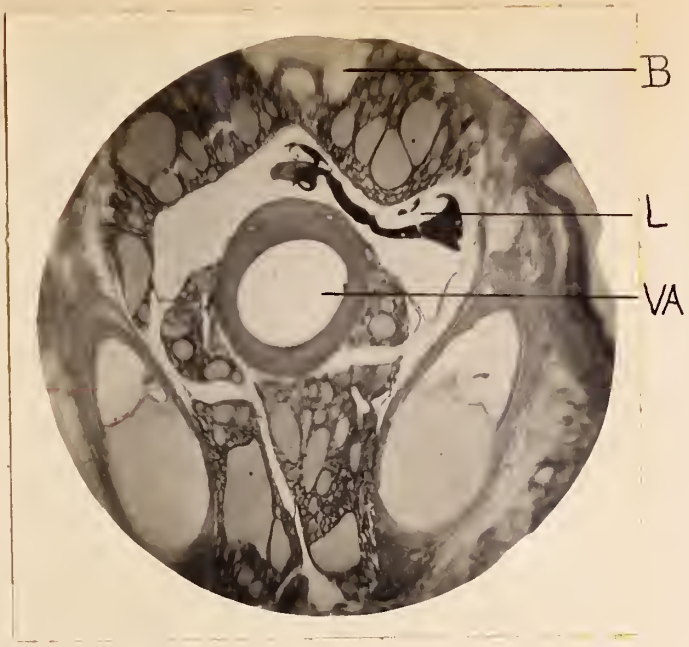

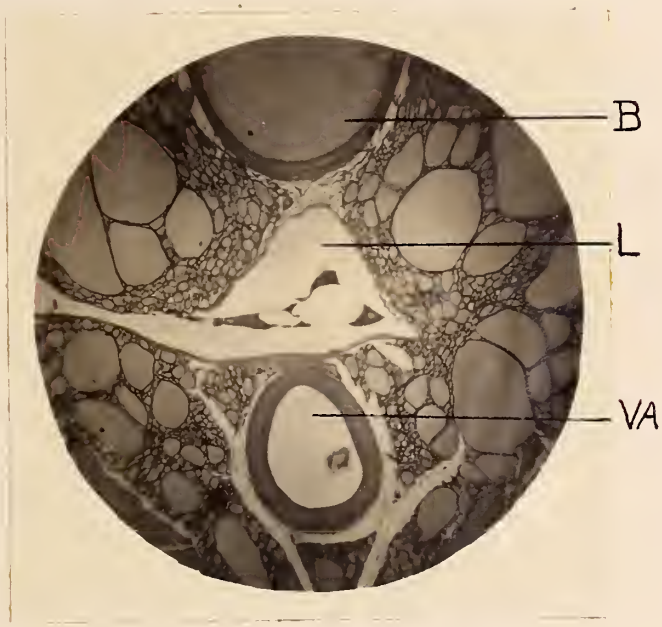

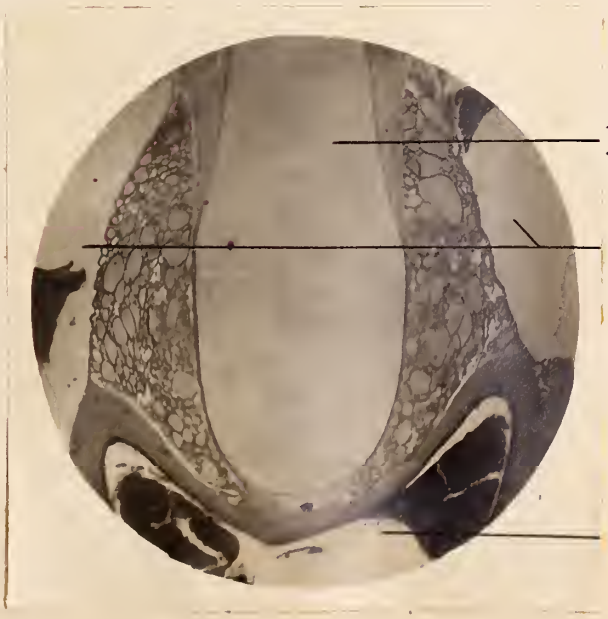

Fig 16

Fig. 17. Graphic reconstruction (x25) of the thyroid lymph sinus (cross-hatched areas) in a 15.4 cm. salmon smolt. The thyroid of the same fish is illustrated in figure 13. At "X" the ventral vessel communicates with the dorsal through lateral channels, and at "D" drains into the neighboring lymphatics of the throat region. I, II, III, and IV, aortic arches; COM, commissural arteries which unite caudally into a single median hypobranchial artery.

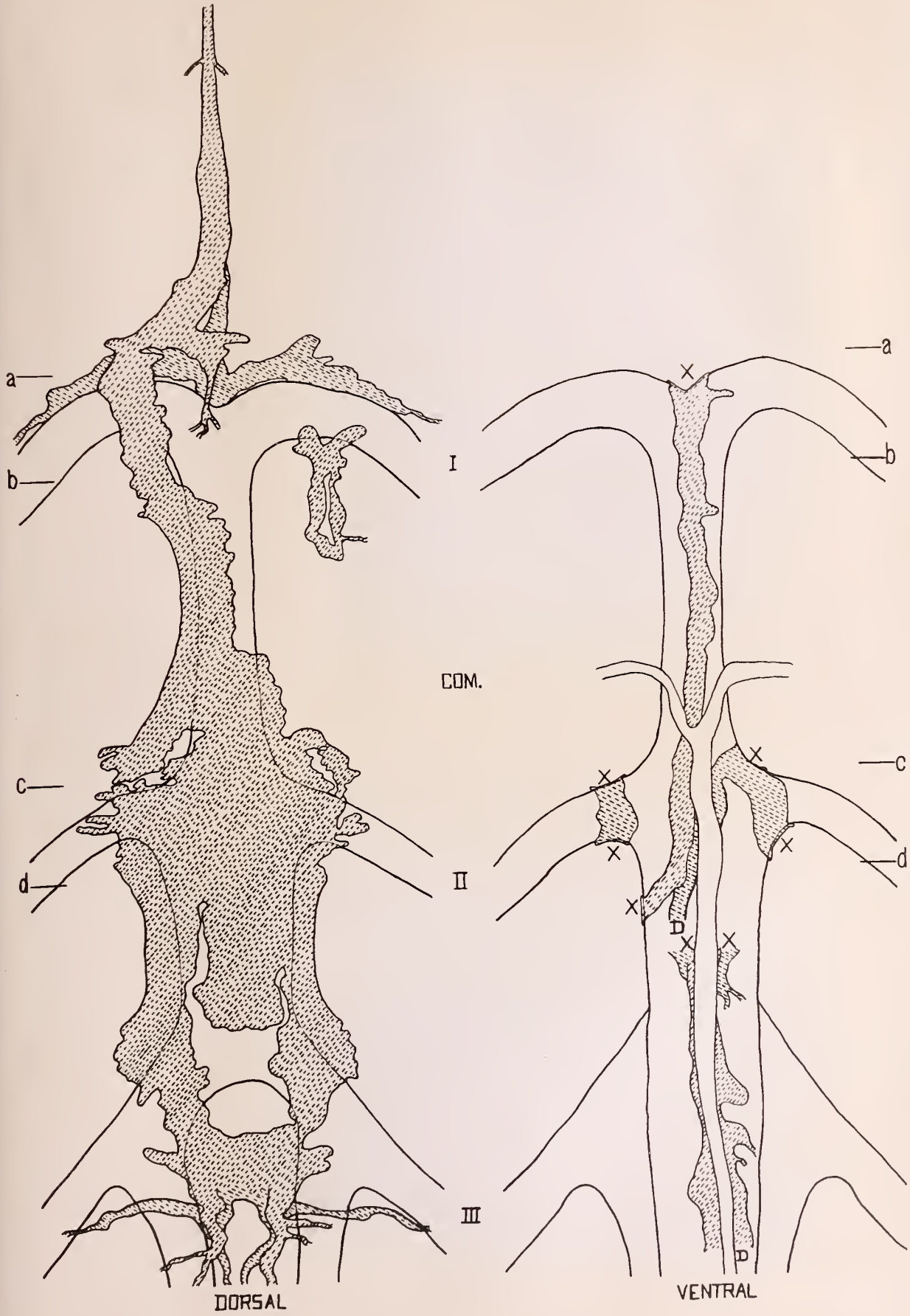

Fig. 17

Fig. 18. Photomicrograph (x45) of a transverse section of the thyroid of a 14.2 cm. smolt. The thyroid is in an extremely hyperplastic condition as shown by the tufting of the empty follicles and the presence of basophylic colloid in the neighboring lymphatics (L). B, basibranchial; VA, ventral aorta. Haematoxylin and eosin.

Fig. 19. Photomicrograph (x175) of thyroid follicles of a 10.2 cm. parr, showing a low cuboidal epithelium. PV, peripheral vacuoles of chromophobic colloid. Haematoxylin and eosin.

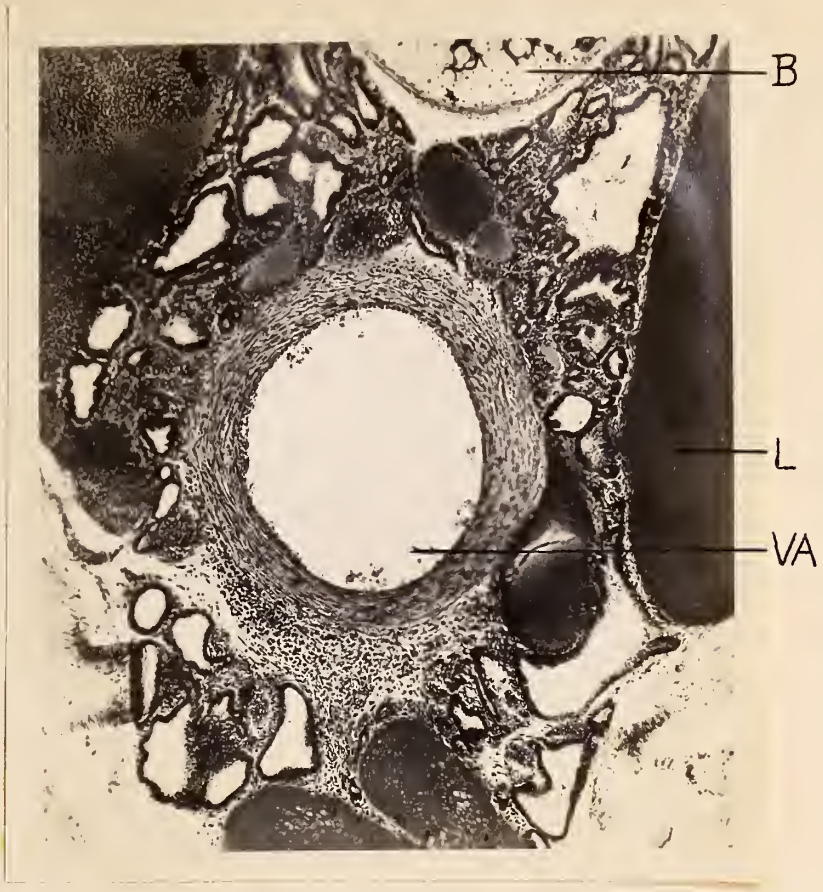

Fig. 18

Fig. 19

Fig. 20. Photomicrograph (x175) of thyroid follicles of a 13.2 cm. smolt thyroid to show the cuboidal epithelium. VA, ventral aorta; Pm, pigment cell. Haematoxylin and eosin.

Fig. 21. Photomicrograph (x68) of thyroid follicles of a 90 cm. adult salmon thyroid to show the gland in a state of involution. Fo, large macroscopic follicle; Er, erythrocyte in the colloid of a follicle. Haematoxylin and eosin.

Fig. 20

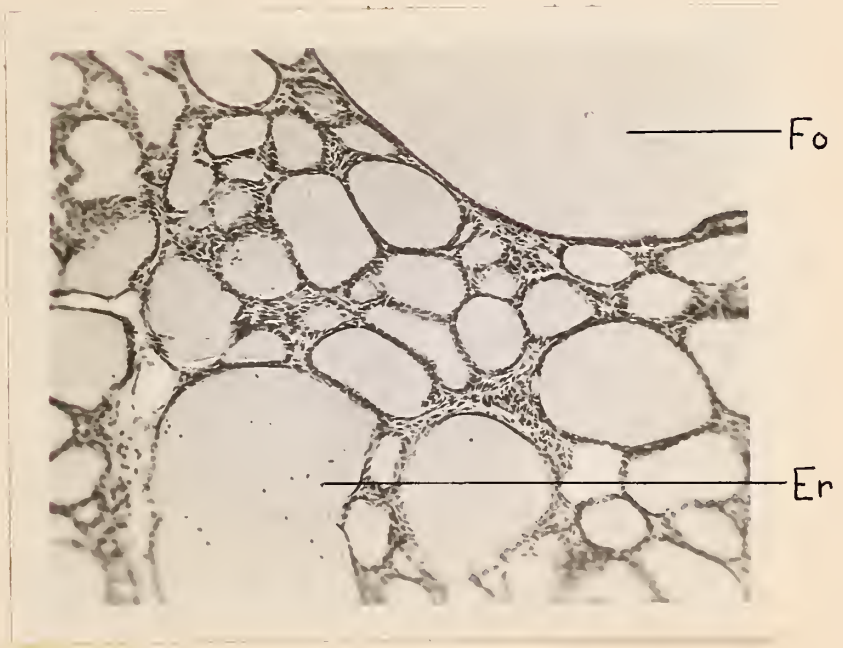

Fig. 21

Fig. 22. Photomicrographs (x80) of the testes of salmon parr taken August 31, 1938. a, (11.1 cm. fish) is rapidly attaining sexual maturity while b, (10.1 cm. fish) shows no evidence of such a change. Haematoxylin and eosin.

Fig. 22a

Fig. 22 b

Fig. 23. Photomicrographs (x80) of the gonads of salmon parr taken on November 16, 1937. a, partially spent, 12.5 cm. male; and b, immature 13.2 cm. female. Haematoxylin and eosin.

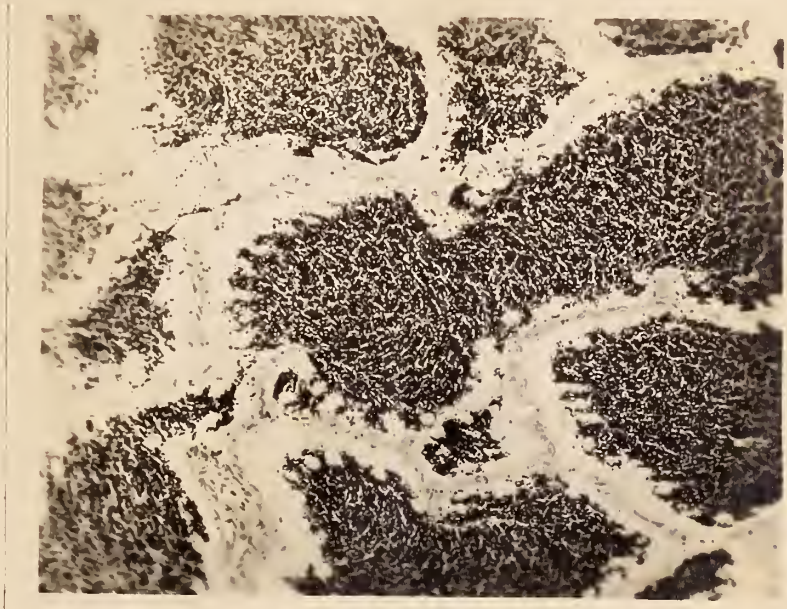

Fig. 23a

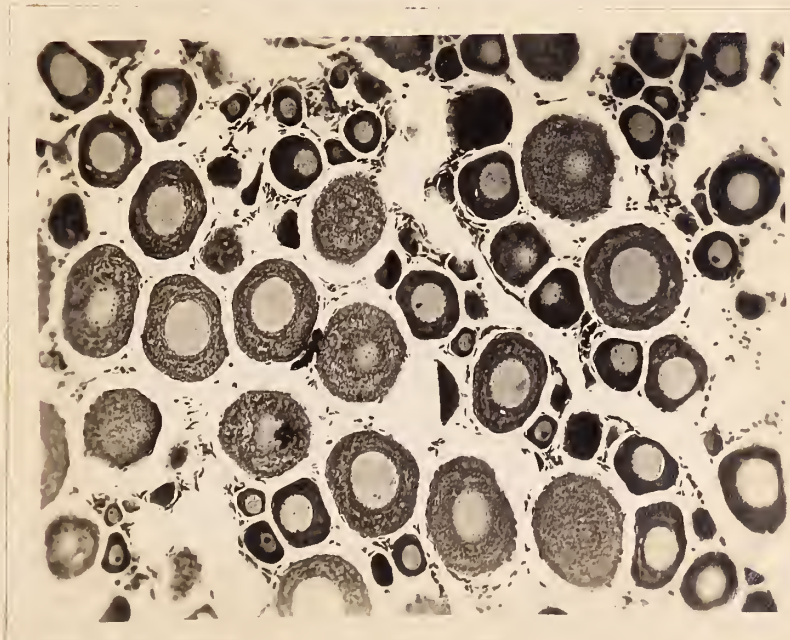

Fig. 23b

AUTOBIOGRAPHICAL NOTES

William Stewart Hoar, born in Moncton, New Brunswick, Canada, August 31st, 1913. Parents, George W. Hoar and Nina B. Steeves Hoar.

Attended public and high schools in Moncton, N. B., leading the graduating class of the latter school in June, 1930.

Lord Beaverbrook scholar to the University of New Brunswick in September, 1930. B. A. degree with first class honors in Biology and Geology in May, 1934.

Obtained the Grammar School Teacher's license for the Province of New Brunswick in August, 1934.

Demonstrator and graduate student in the Department of Zoology at the University of Western Ontario, London, Canada, from September, 1934 to June, 1936. M. A. degree with first class honors in June, 1936, majoring in Histology and Embryology. Thesis, "The Development and Histology of the Swim Bladder of the Atlantic Salmon".

Assistant in the Department of Histology and Embryology, Boston University Medical School, from September, 1936 until the present.

Graduate student at Boston University from 1936 to 1939.

Research assistant on the Atlantic Salmon Investigation of the Fisheries Research Board of Canada during the summers of 1935, 1936, 1937, and 1938.

BOSTON UNIVERSITY
1 1719 02482 1813